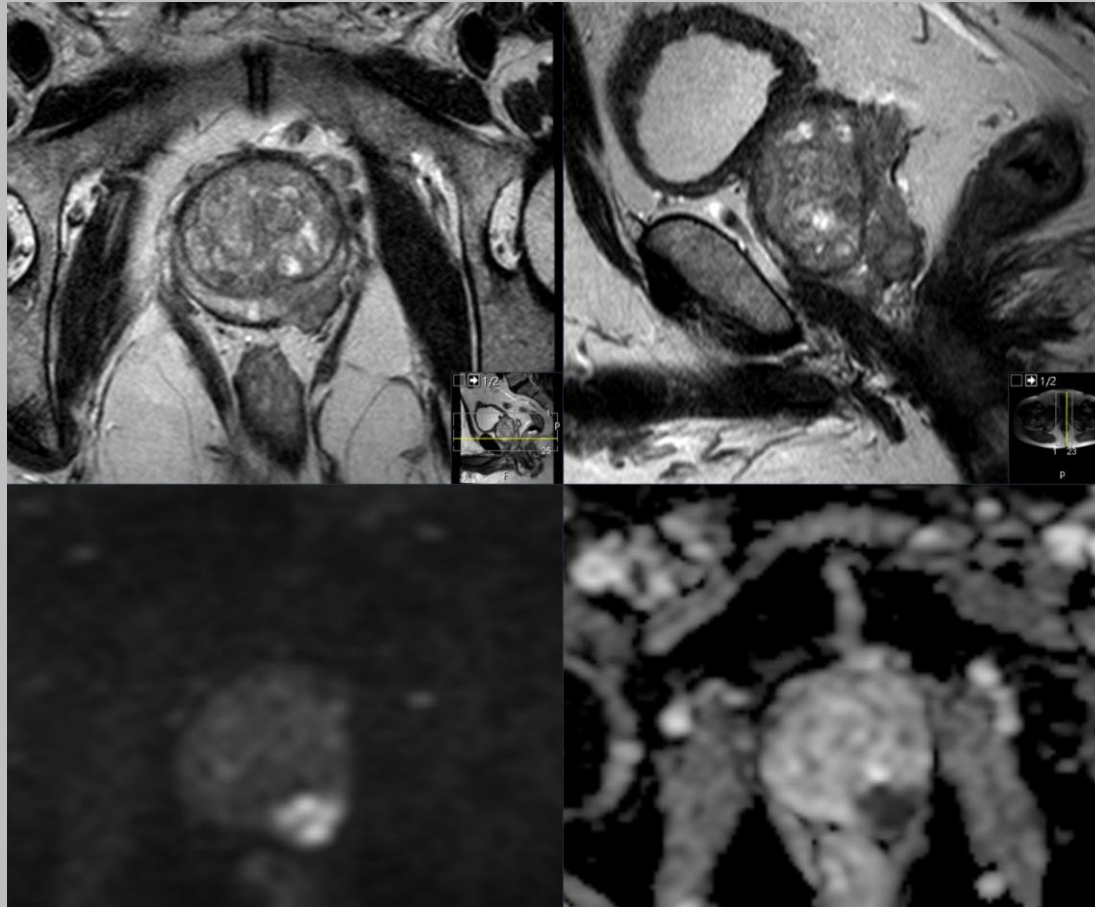


MRT prostata

STADIEINDELNING



Nationella riktlinjer för lokal stadieindelning

STADIEINDELNING

- LOKAL STADIEINDELNING
 - Extraprostatisk extension (EPE)
 - Seminalvesikel-invasion (SVI)
 - Nedre sfinkter (NS)
 - Blåshals

STADIEINDELNING


- LOKAL STADIEINDELNING
 - ***Extraprostatisk extension (EPE)***
 - Seminalvesikel-invasion (SVI)
 - Nedre sfinkter (NS)
 - Blåshals

EXTRAPROSTATISK EXTENSION (EPE) -HISTOLOGISKT

- DEFINITION: tumörväxt utanför "kapseln" (pT3)
- I PAD beskrivs allt från "några körtelrör" till "flera millimeter" växt utanför kapseln
- RISK FÖR POSITIVA MARGINALER VID KIRURGI
- SÄMRE PROGNOSES MED RISK FÖR SPRIDD SJUKDOM

TUMÖRENS VÄXTSÄTT I UTLÅTANDET

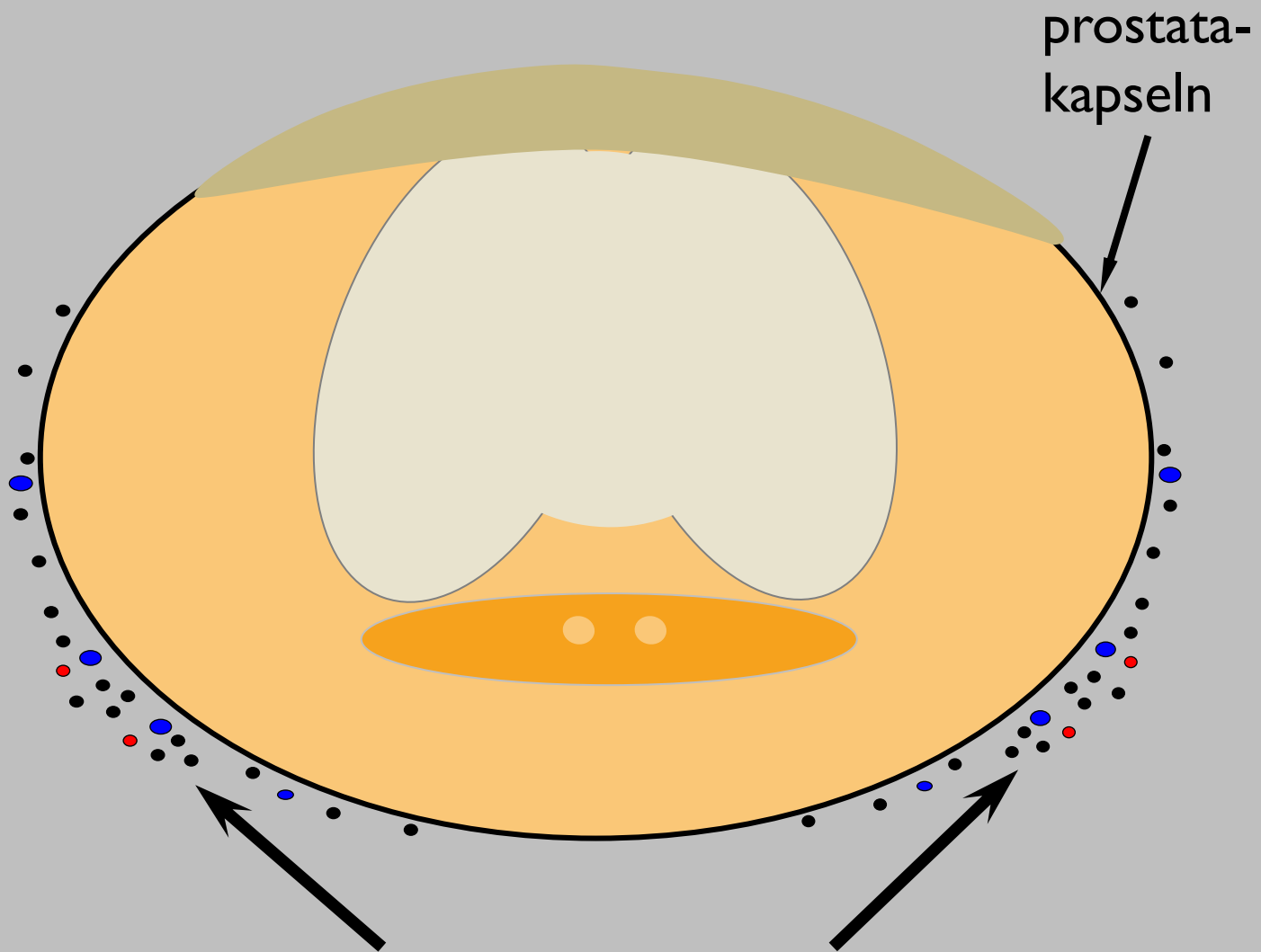
- Bred anläggning mot kapseln ≥ 12 mm
- Buktning av kapseln
- Förtjockad/avbruten kapseln
- Oregelbunden/oskarp kapsel
- Stråkighet ut i periprostatiskt fett
- Utfyllnad i rekto-prostatiska vinkeln
- Mätbar extraprostatisk växt



Erfarenhetsmässigt
ökad risk för
extraprostatisk
tumörväxt

FALLGROPAR

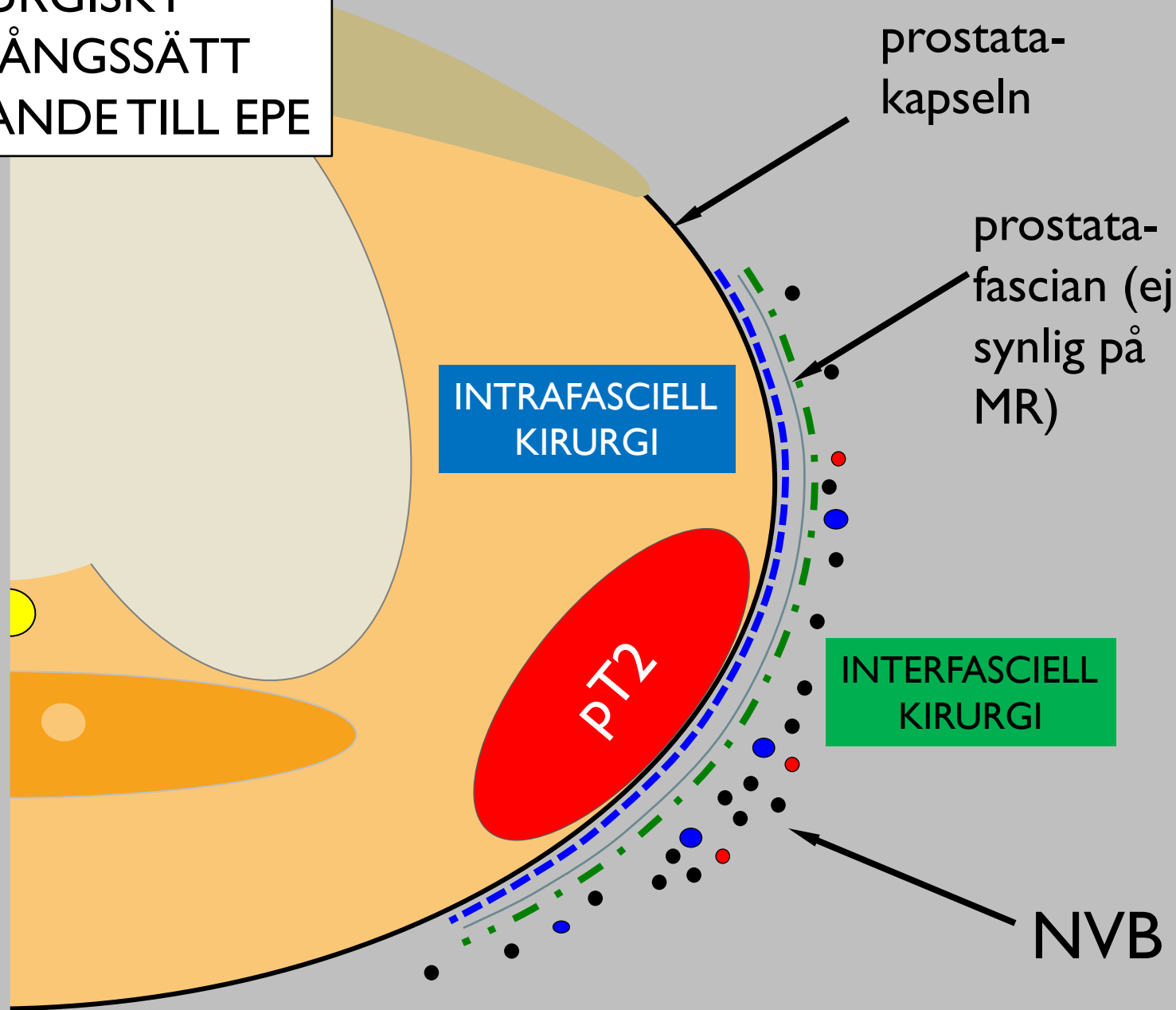
- Det starkast prediktiva tecknet för EPE är mätbar extraprostatisk växt (EPE 5). Övriga tecken är indirekta och baserade på erfarenheter från uppföljningar av PAD efter multidisciplinär konferens (MDK) inför kirurgi.
- Vid indirekta tecken till EPE är det viktigt att bedöma alla tillgängliga bilder för att undvika övergradering på grund av partiella volymseffekter och periprostatiska vener.



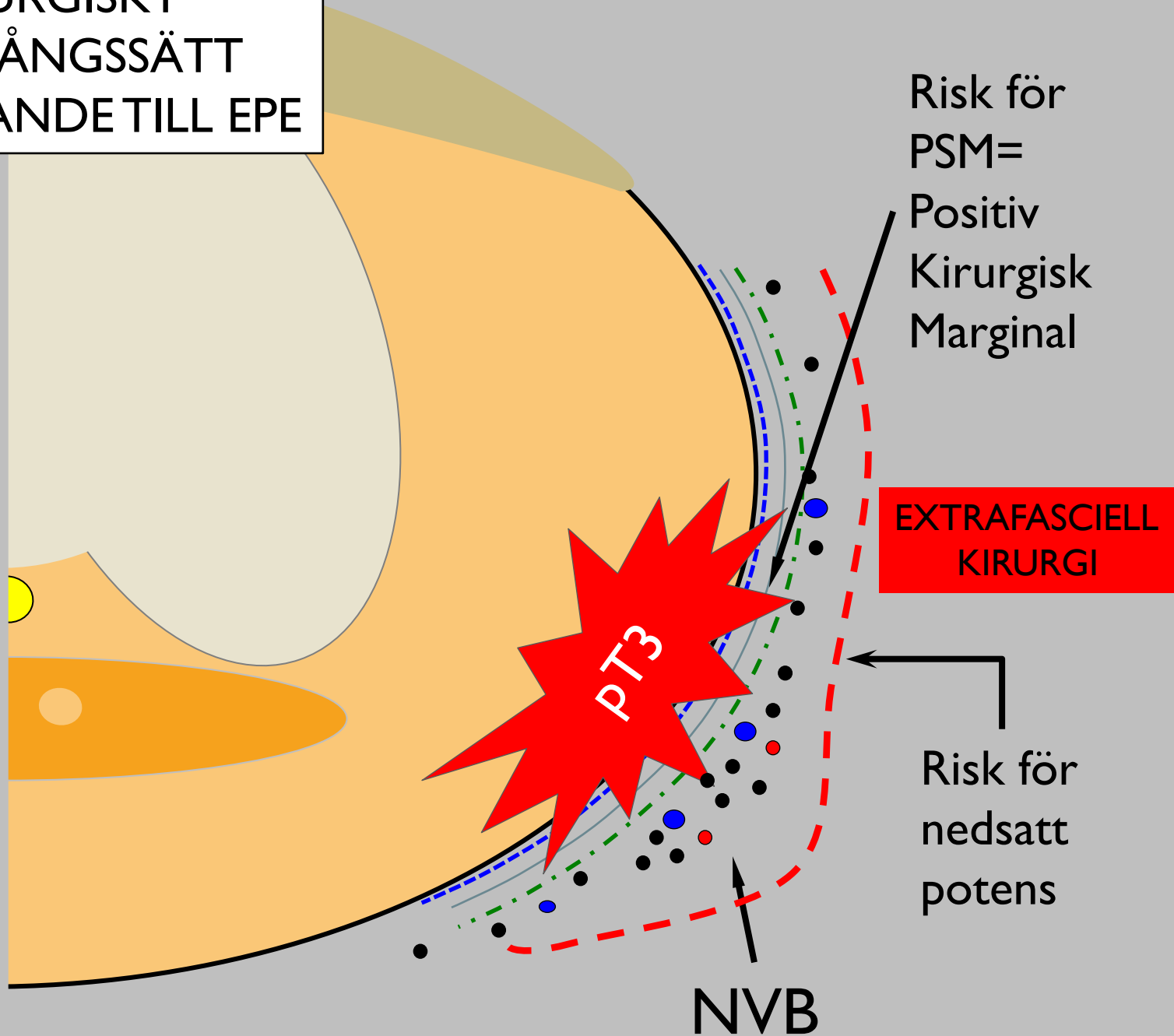
prostata-
kapseln

Neurovaskuläre Buntten
=NVB

VAL AV KIRURGISKT
TILLVÄGAGÅNGSSÄTT
I FÖRHÅLLANDE TILL EPE



VAL AV KIRURGISKT
TILLVÄGAGÅNGSSÄTT
I FÖRHÅLLANDE TILL EPE



GRADERING VID STADIEINDELNING

LIKERT: skala 1-5 för riskbedömning

1 = mycket stor sannolikhet negativt

2 = stor sannolikhet negativt

3 = osäkert

4 = stor sannolikhet positivt

5 = mycket stor sannolikhet positivt

GRADERING VID STADIEINDELNING

Likert

1

2

3

4

5

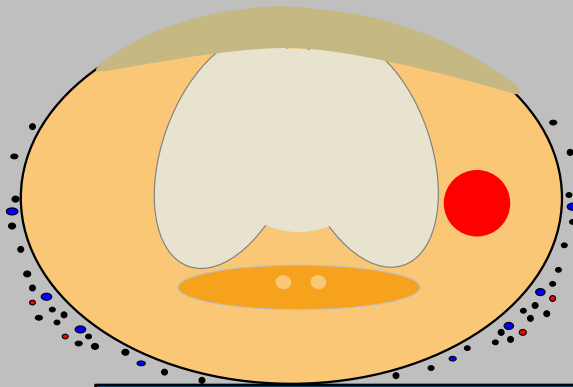
—

?

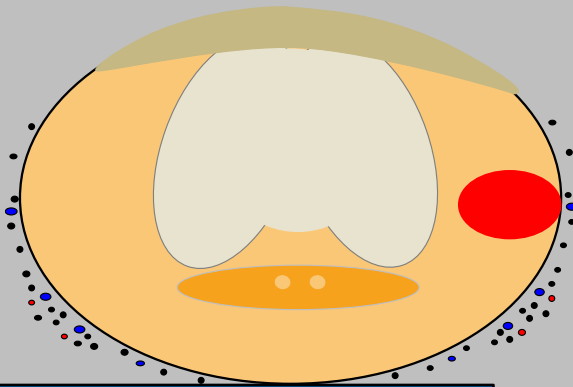
+

Kortad gradering

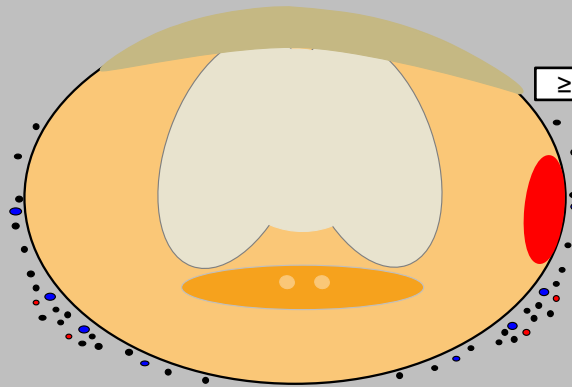
EXTRAPROSTATISK EXTENSION (EPE)



EPE 1

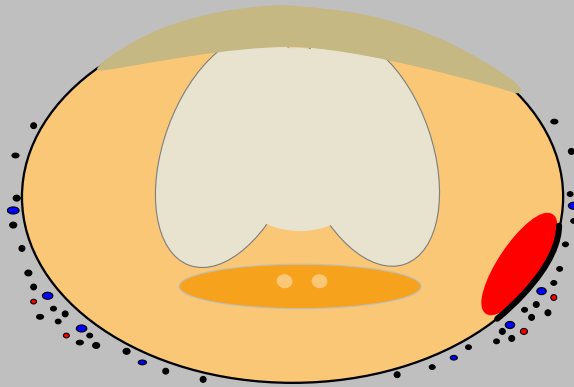


EPE 2

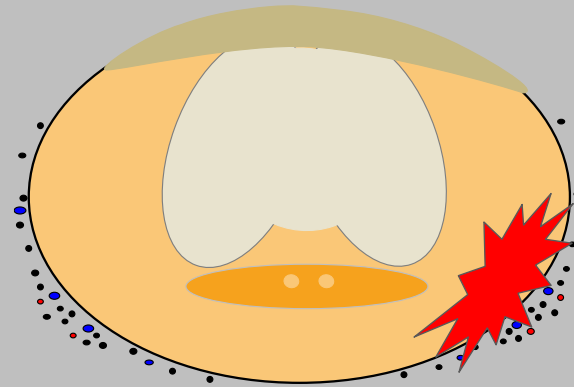


EPE 3

?

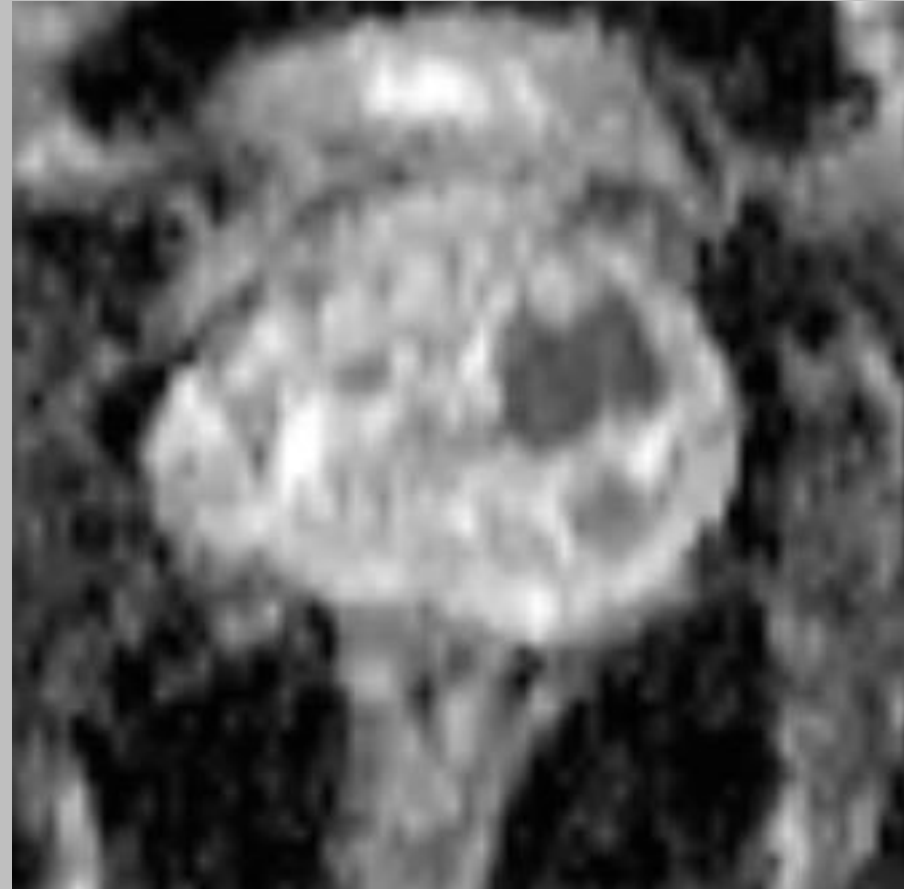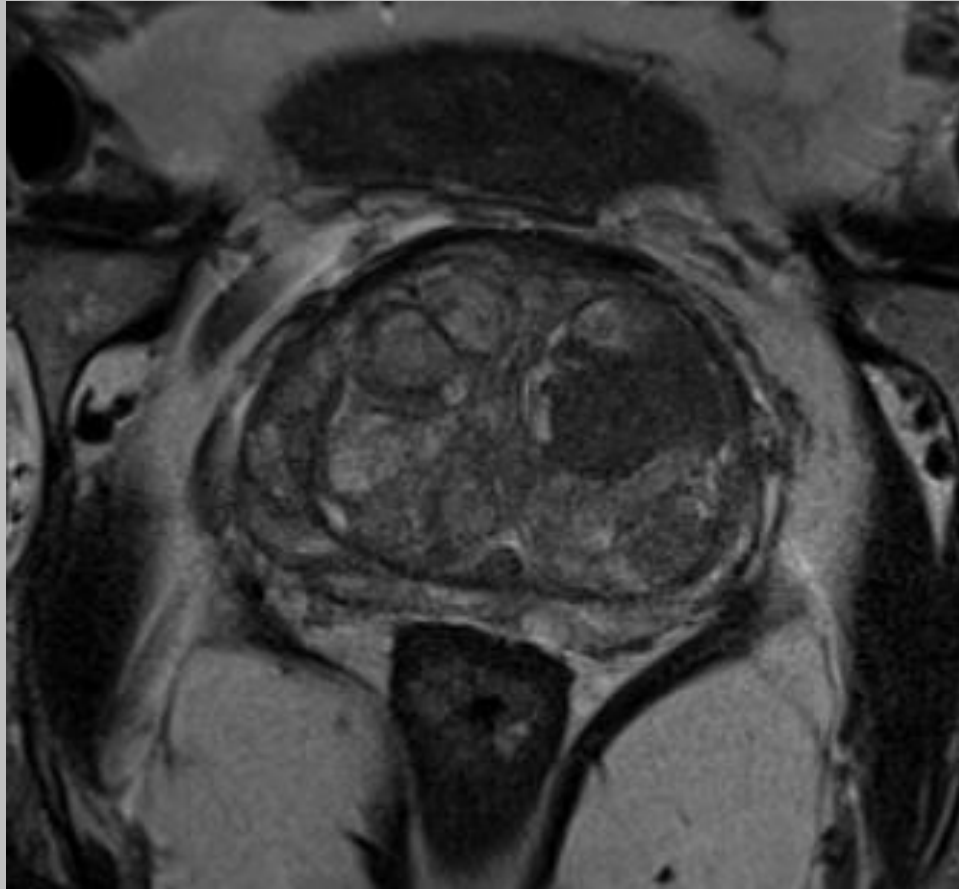
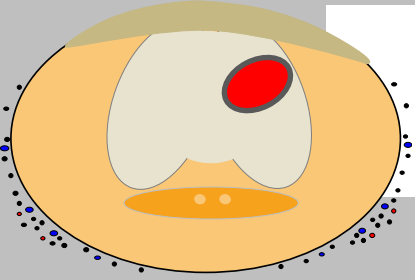


EPE 4




EPE 5


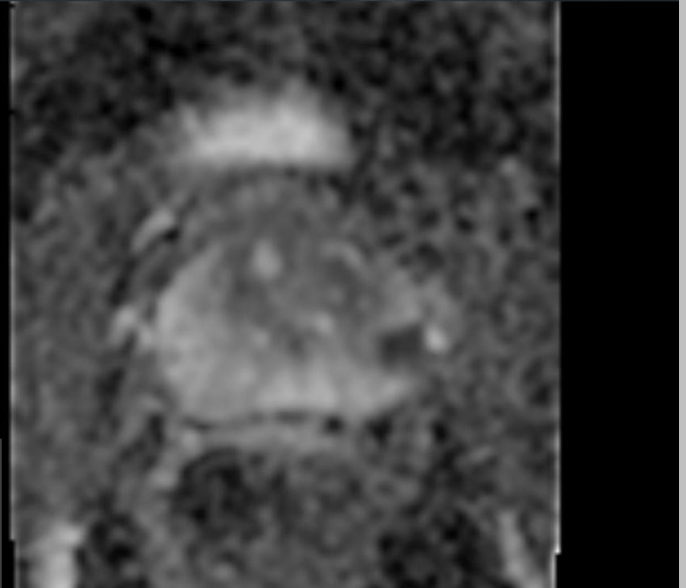

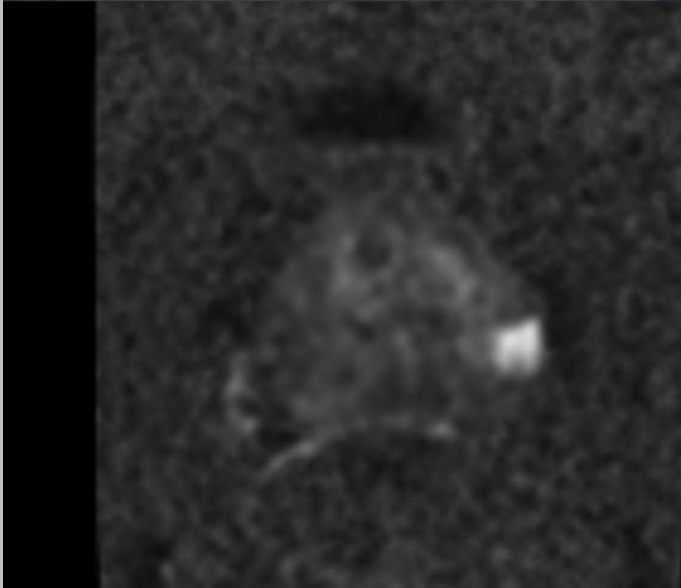
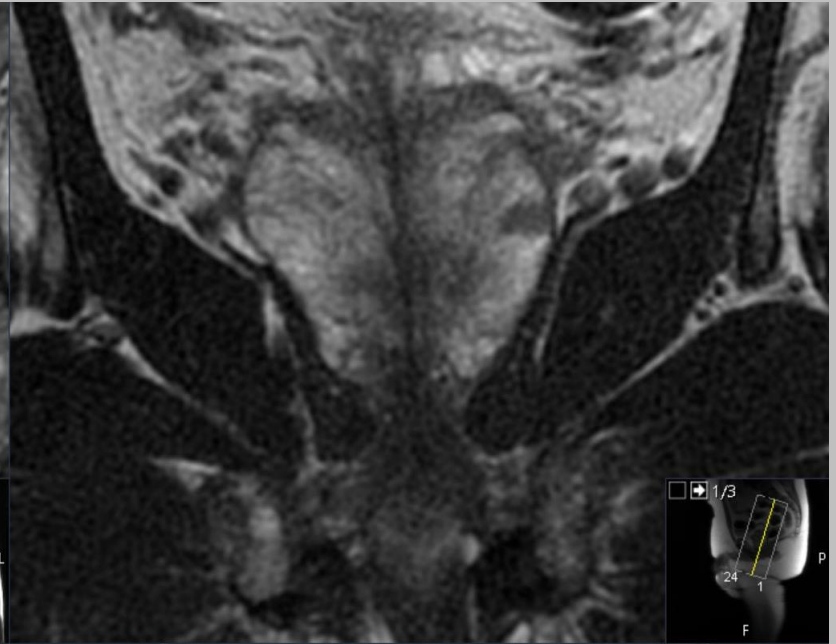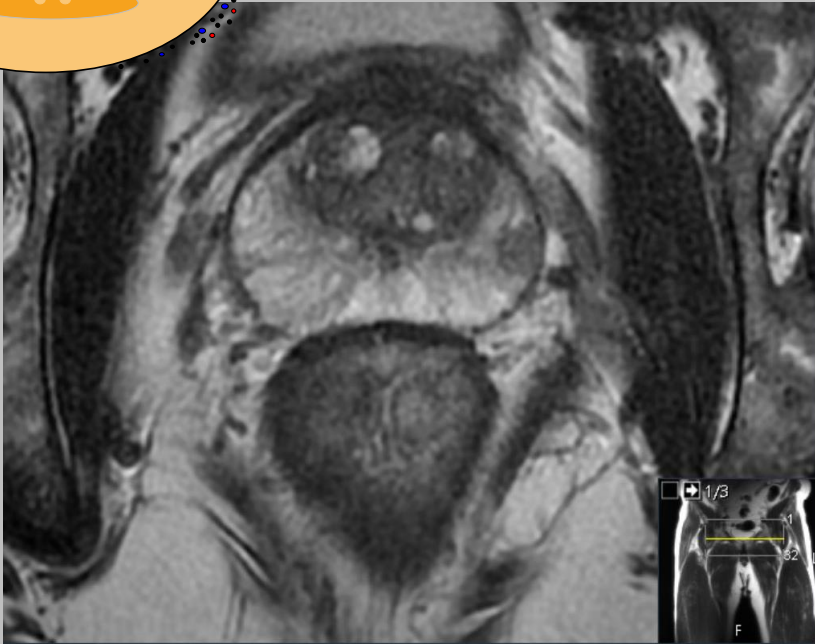
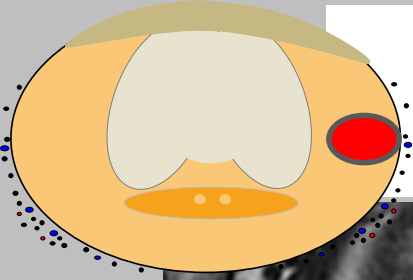
EXTRAPROSTATISK EXTENSION (EPE)



EPE I

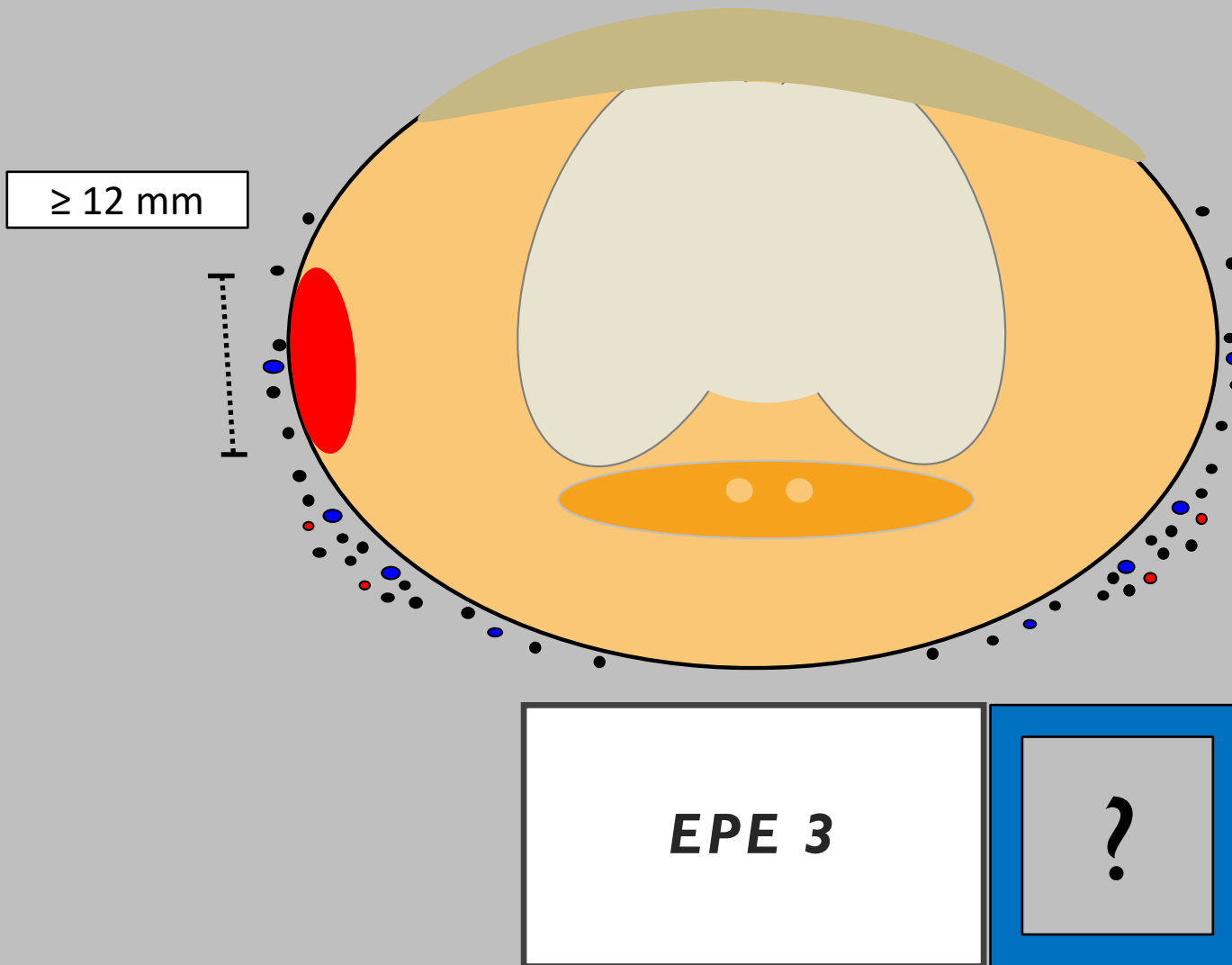


EXTRAPROSTATISK EXTENSION (EPE)

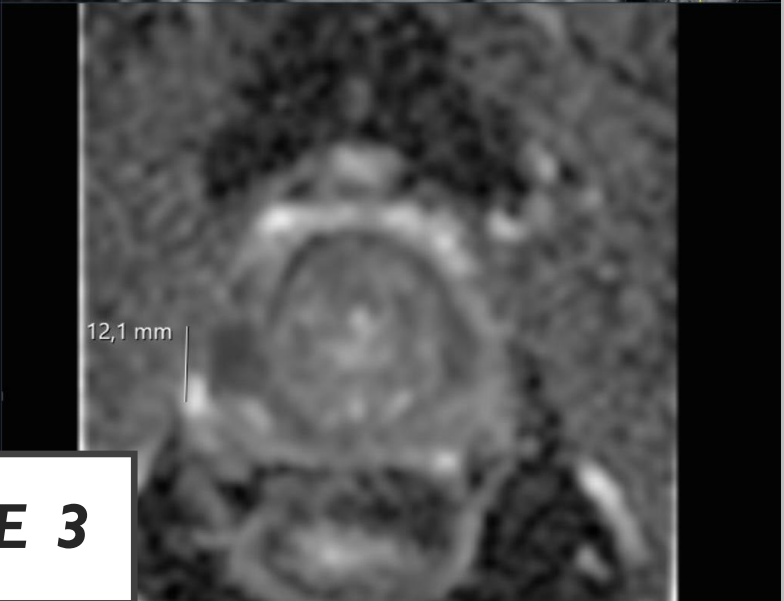
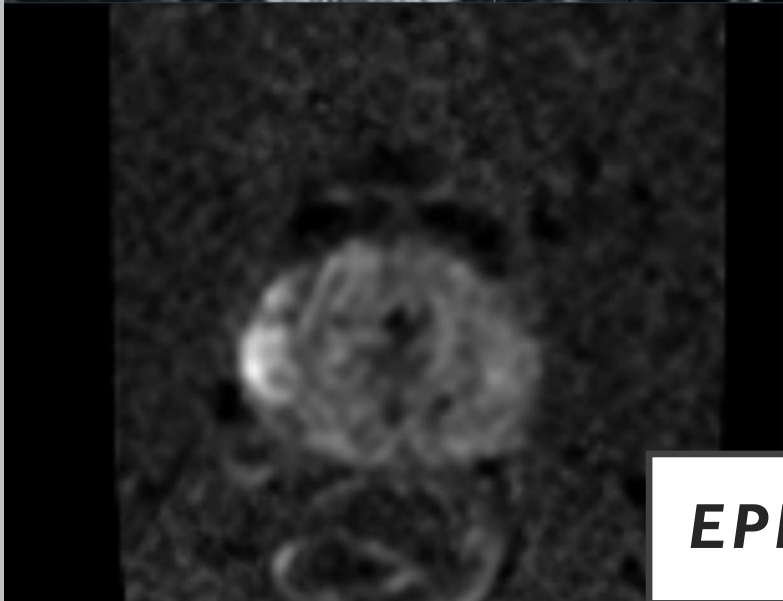
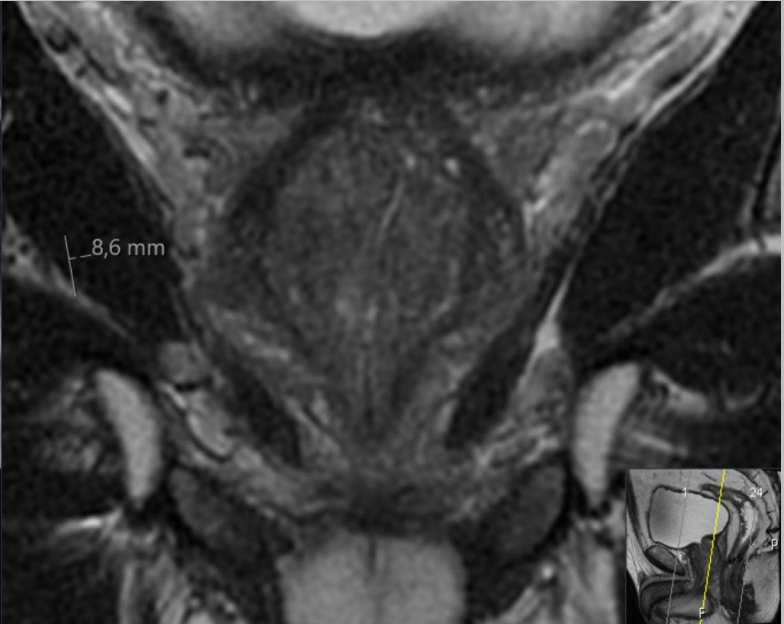
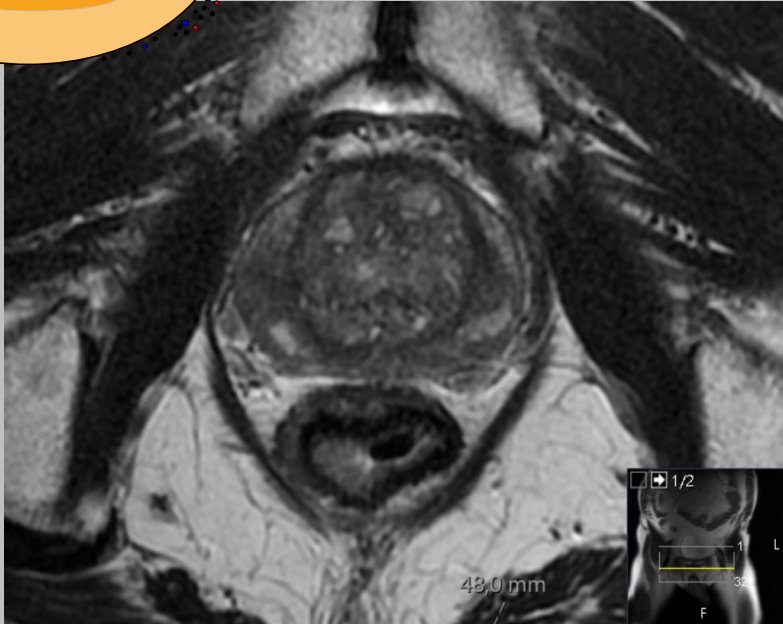
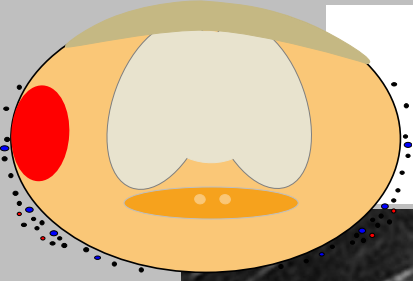


EPE 2

EXTRAPROSTATISK EXTENSION (EPE)

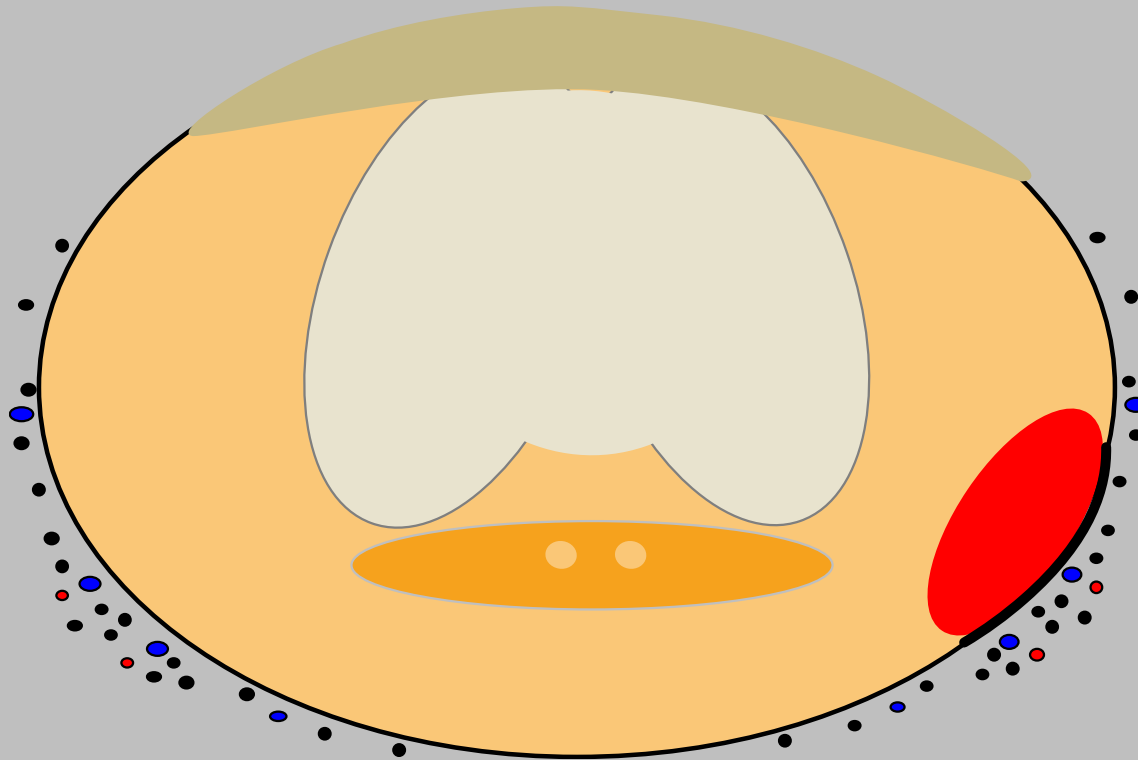


EXTRAPROSTATISK EXTENSION (EPE)



EPE 3

EXTRAPROSTATISK EXTENSION (EPE)

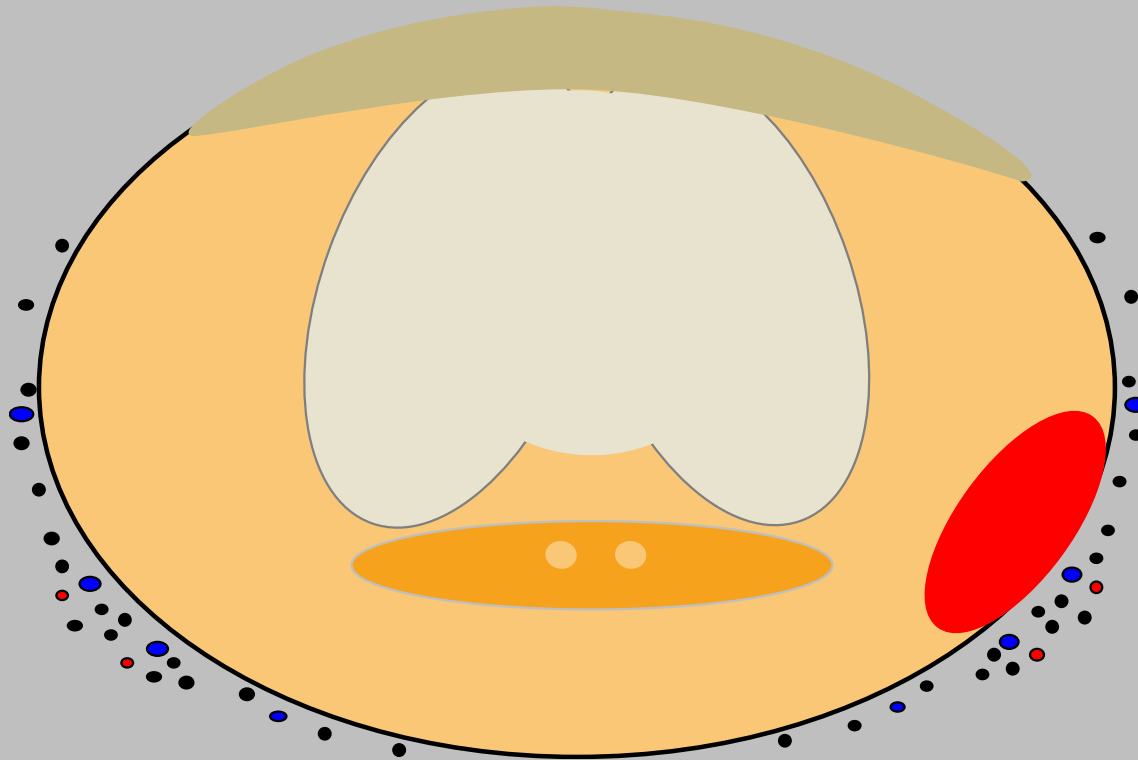


Förtjockad kapsel

EPE 4



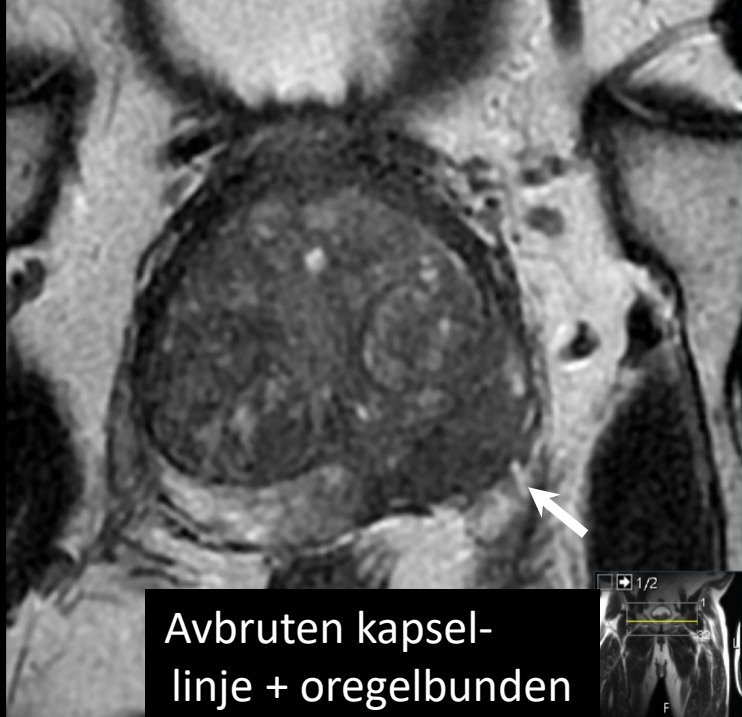EXTRAPROSTATISK EXTENSION (EPE)



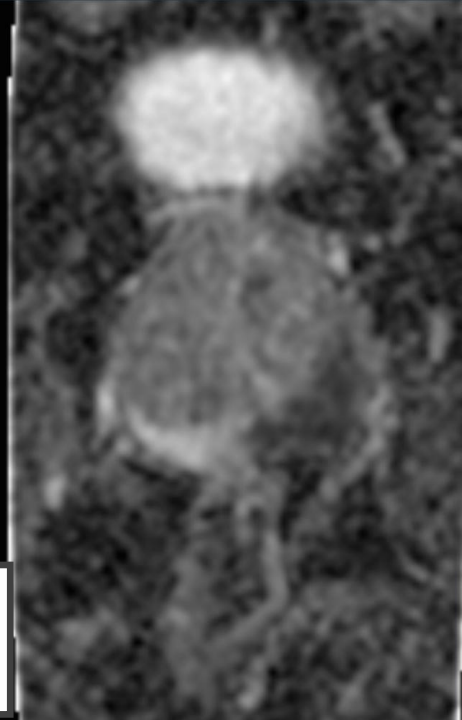
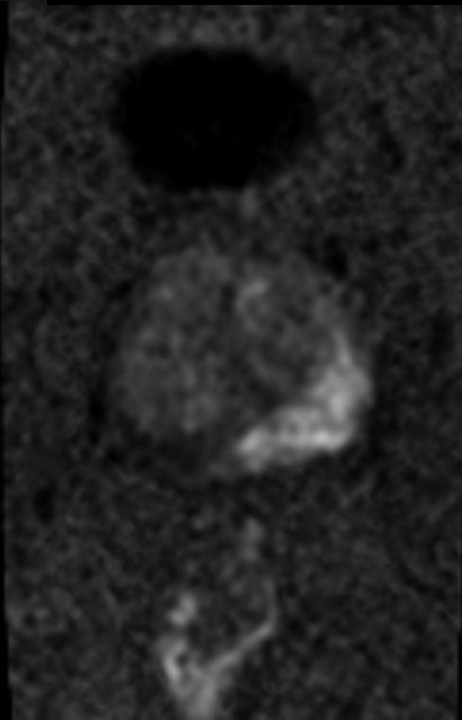
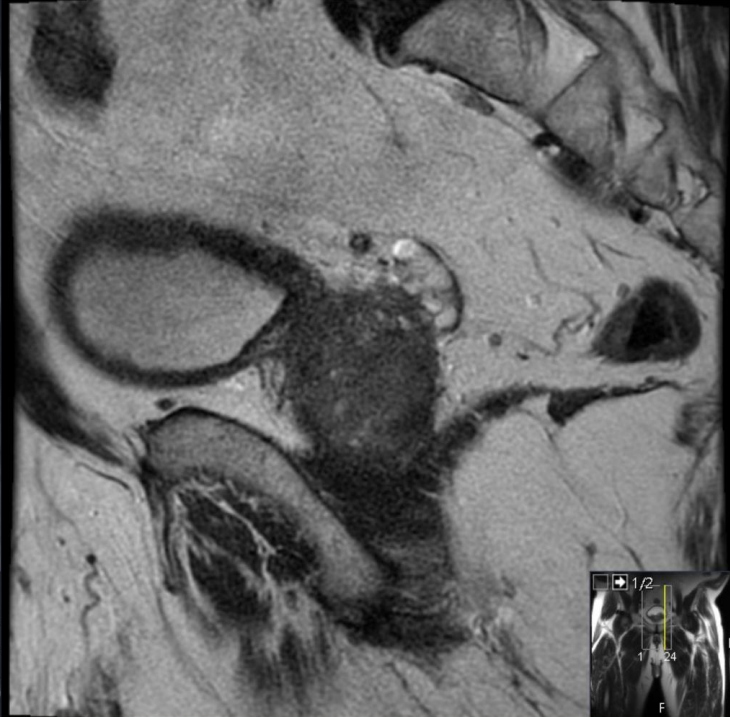
Avbruten kapsel-
linje

EPE 4

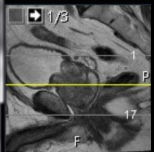




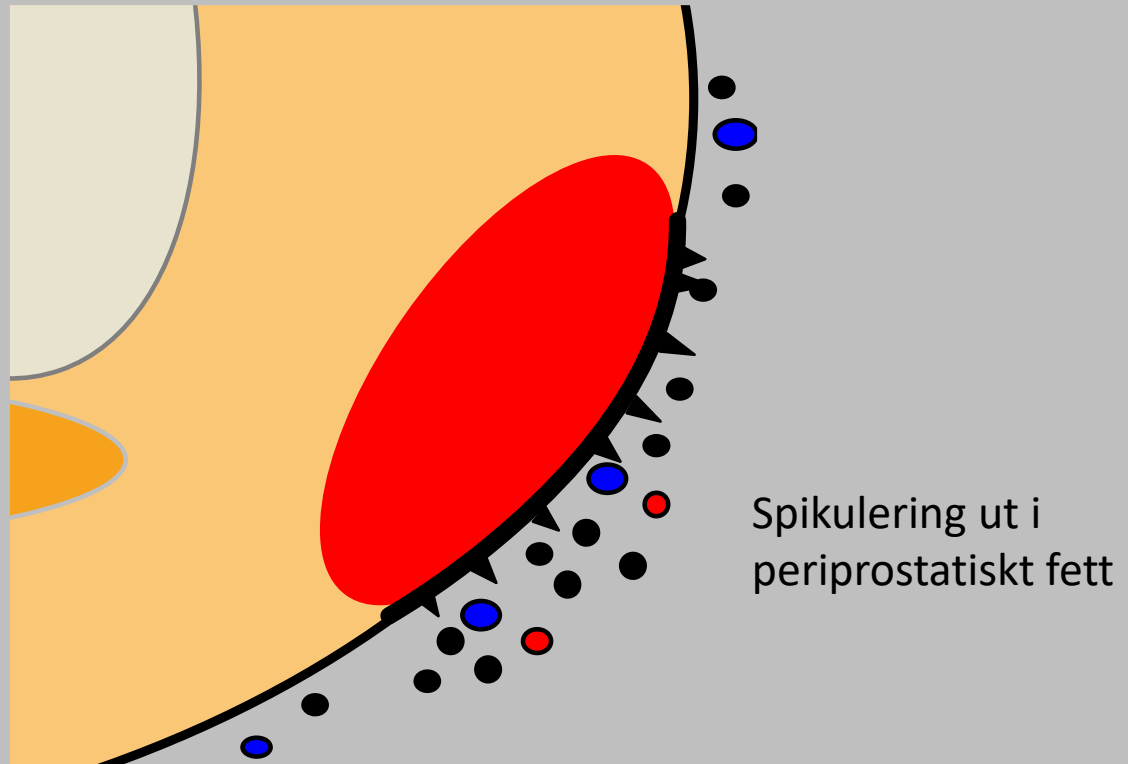
Avbruten kapselinje + oregelbunden



EPE 4

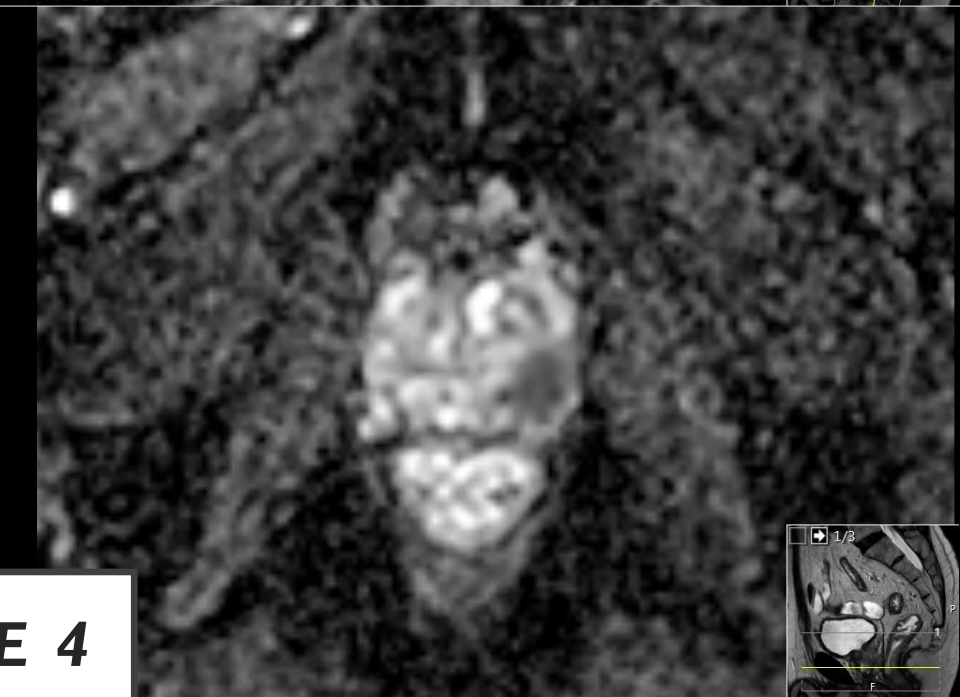
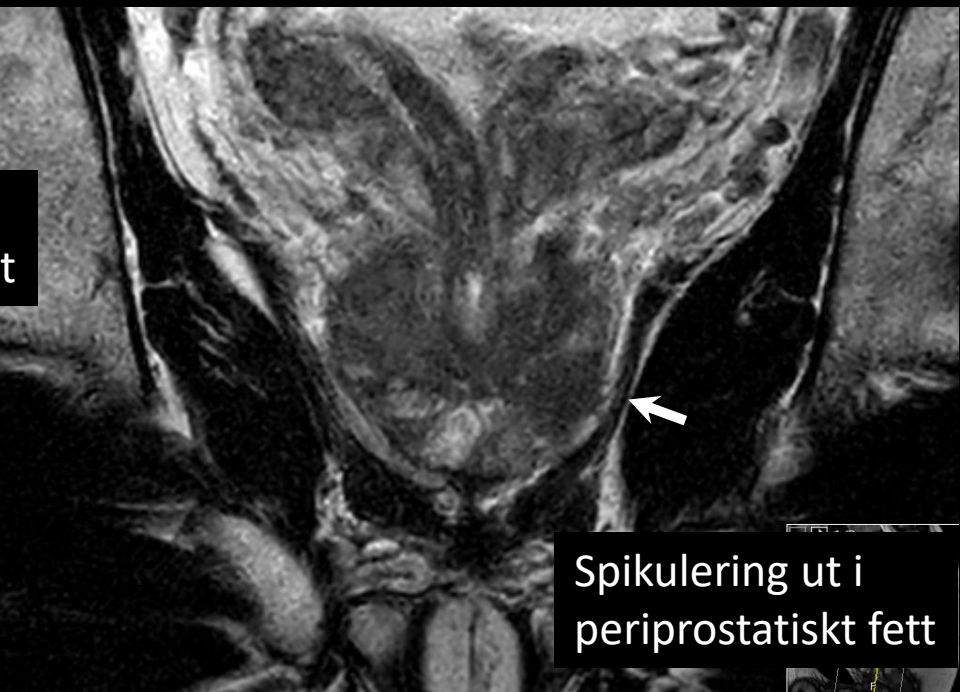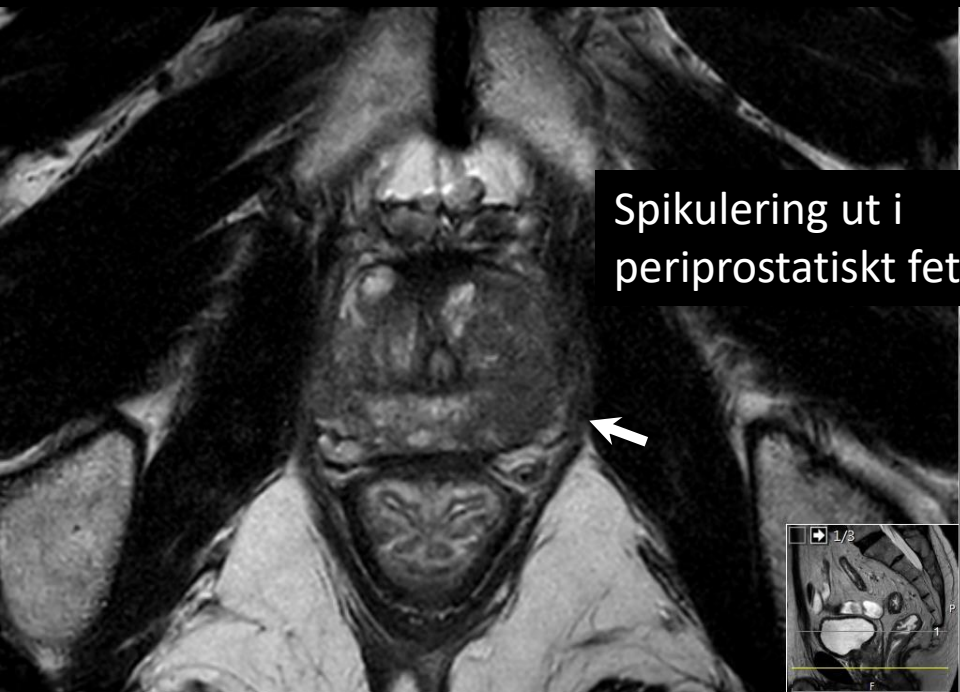


EXTRAPROSTATISK EXTENSION (EPE)



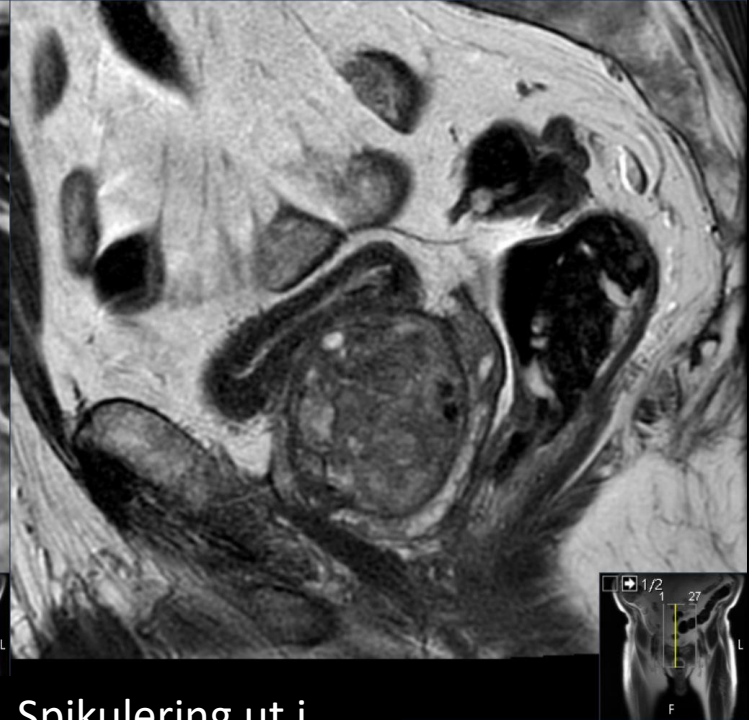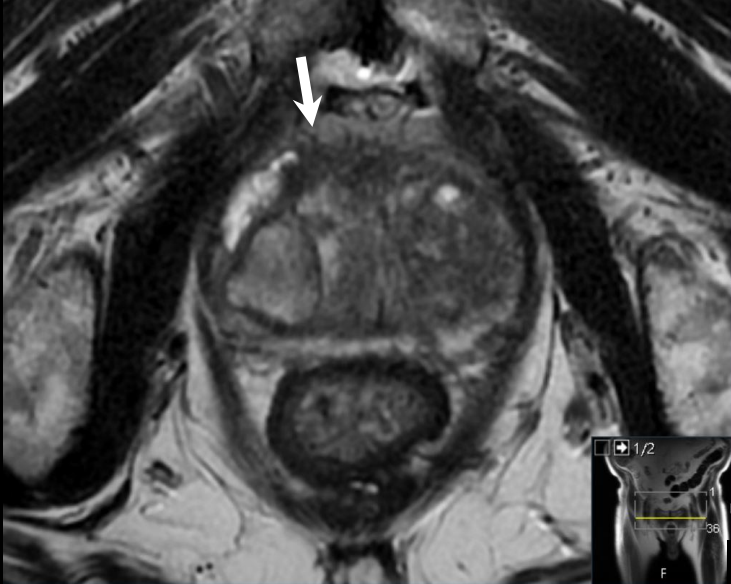EPE 4



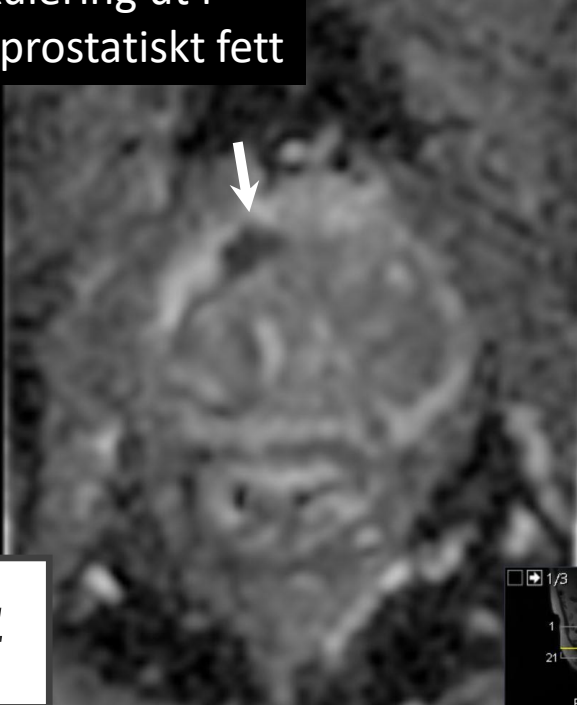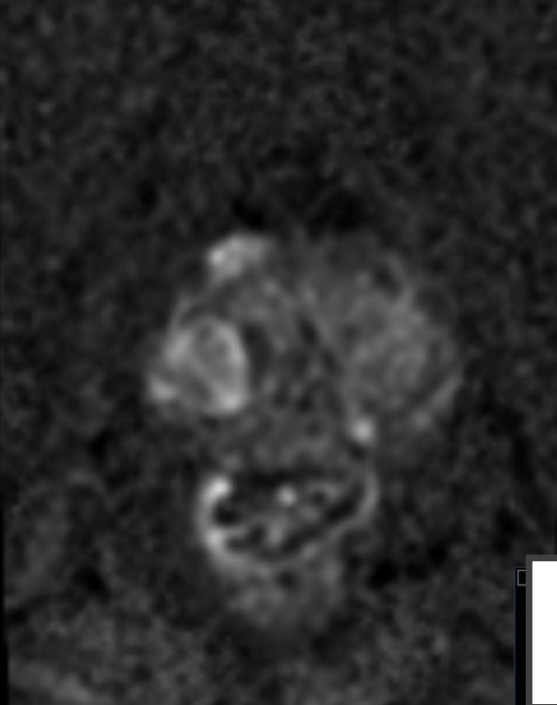


EPE 4

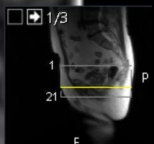
Spikulering ut i periprostatisk fett



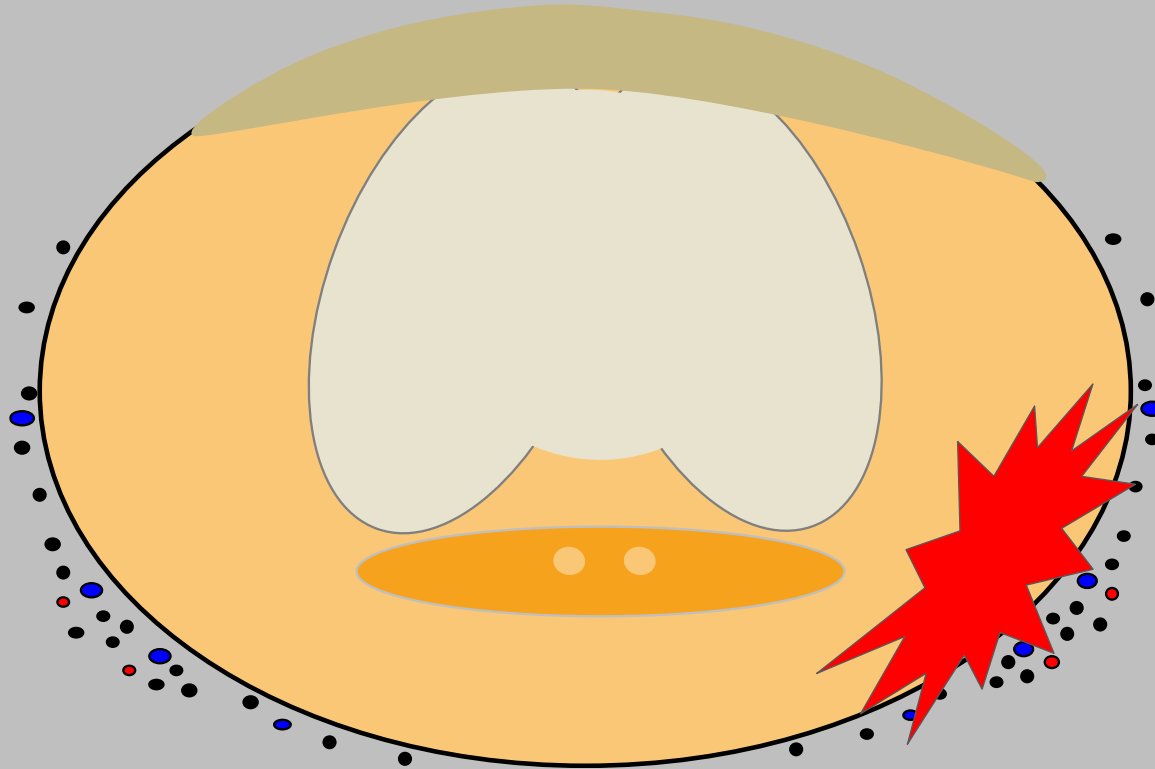
Spikulering ut i periprostatisk fett



EPE 4



EXTRAPROSTATISK EXTENSION (EPE)

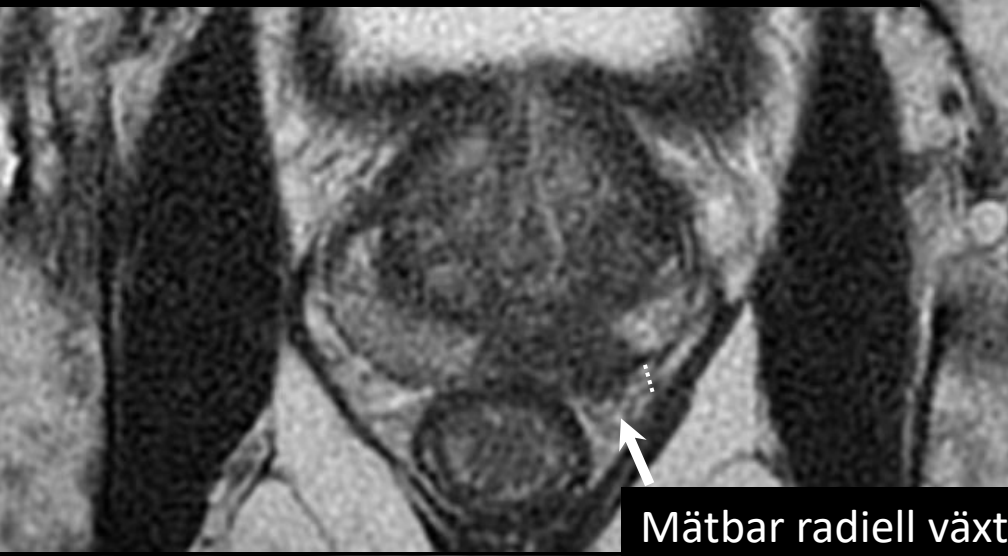

EPE 5

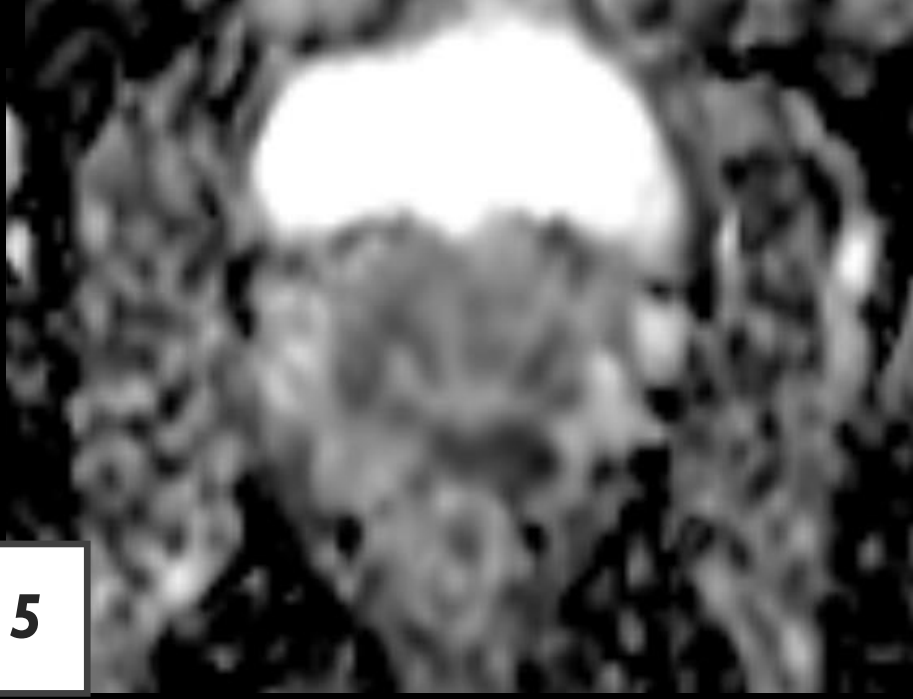
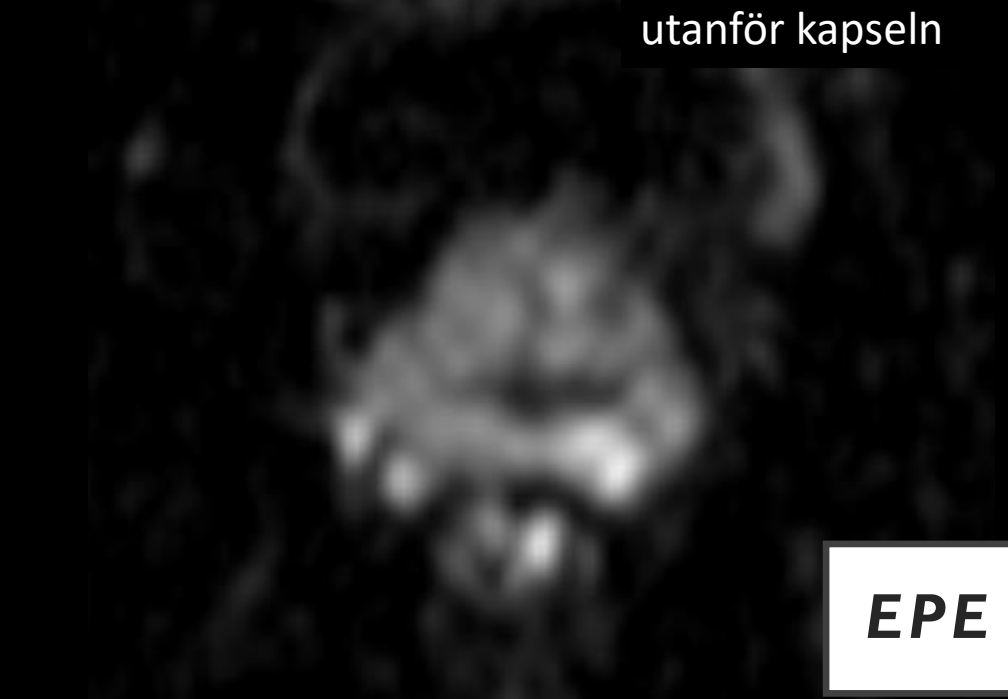
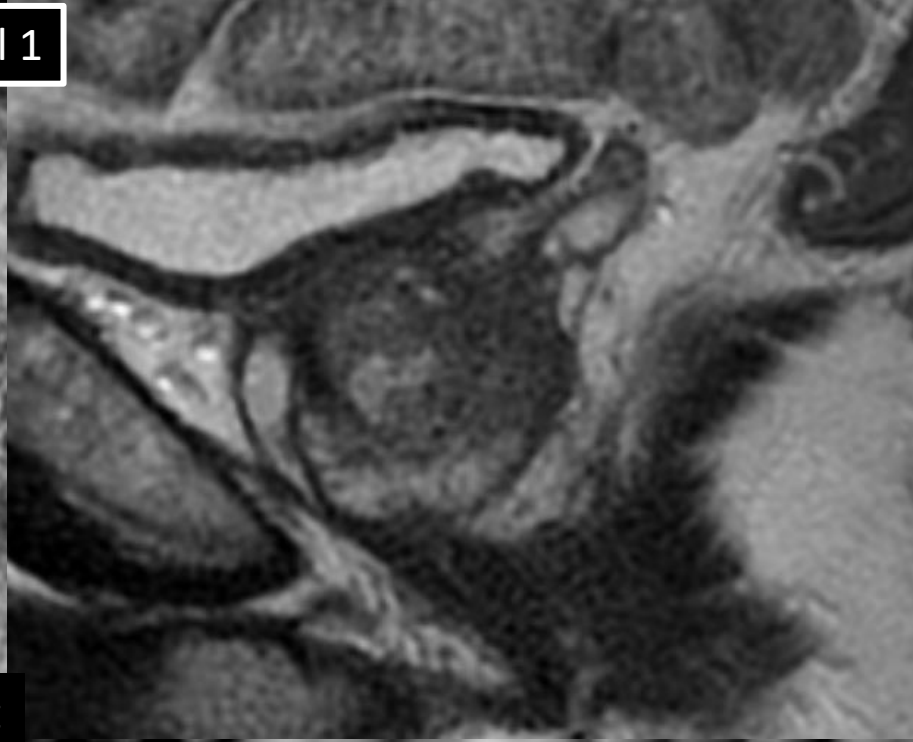


Trots kort anläggning mot kapseln och liten förändring (<15 mm) ses tydlig EPE, vilket vid primärbedömningen ger PI-RADS 5

Fall 1

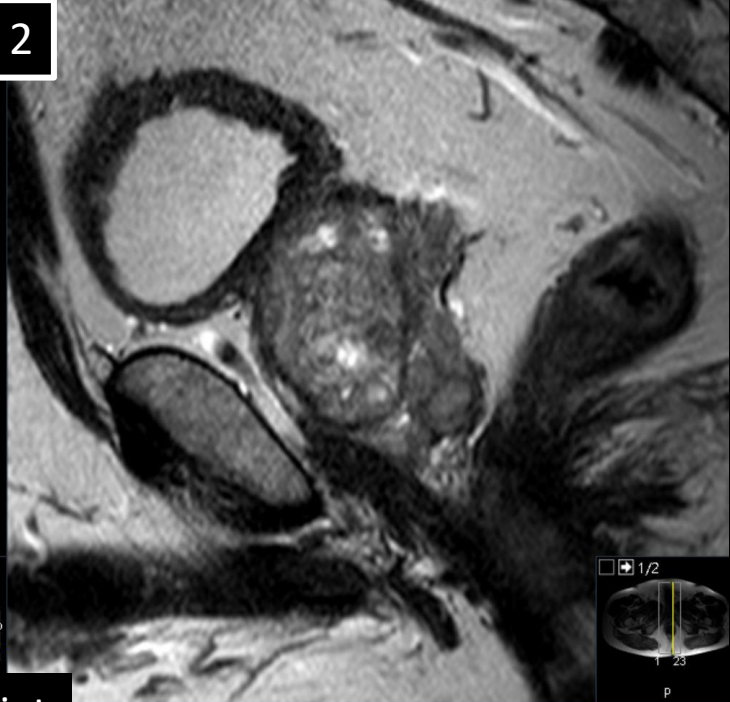
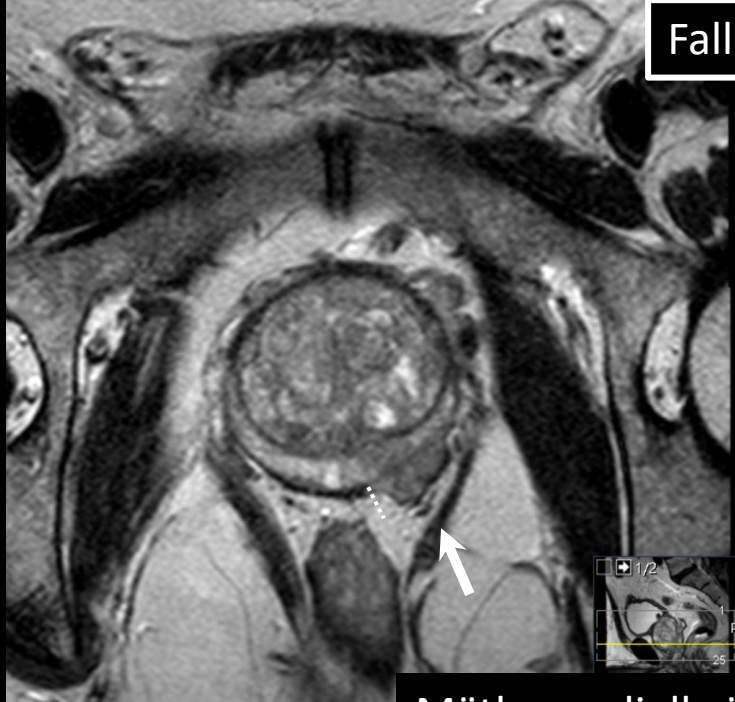

Mätbar radiell växt utanför kapseln

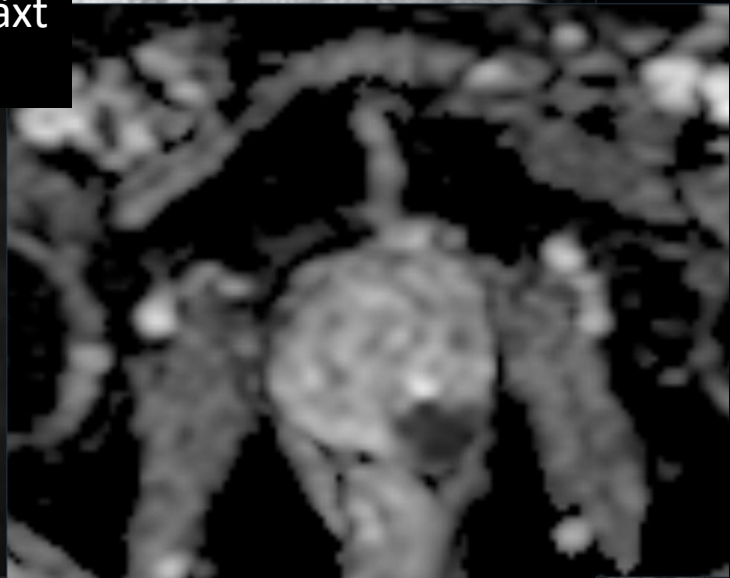
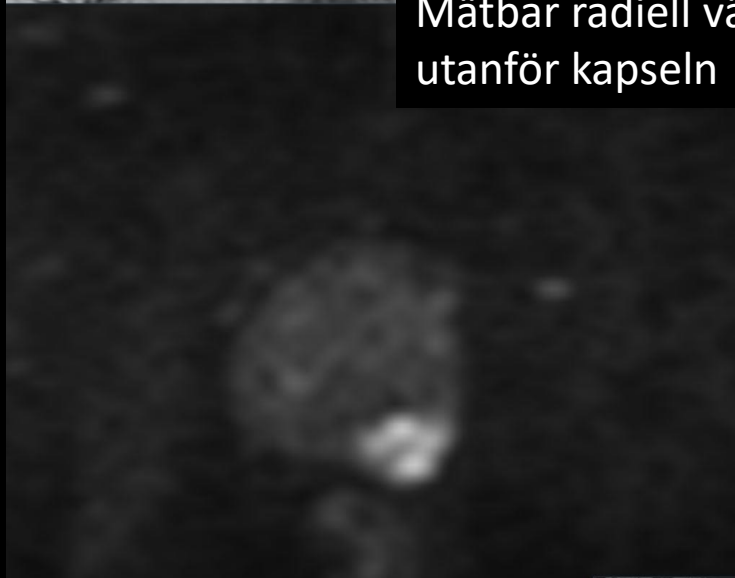

EPE 5

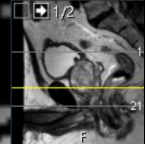Fall 2



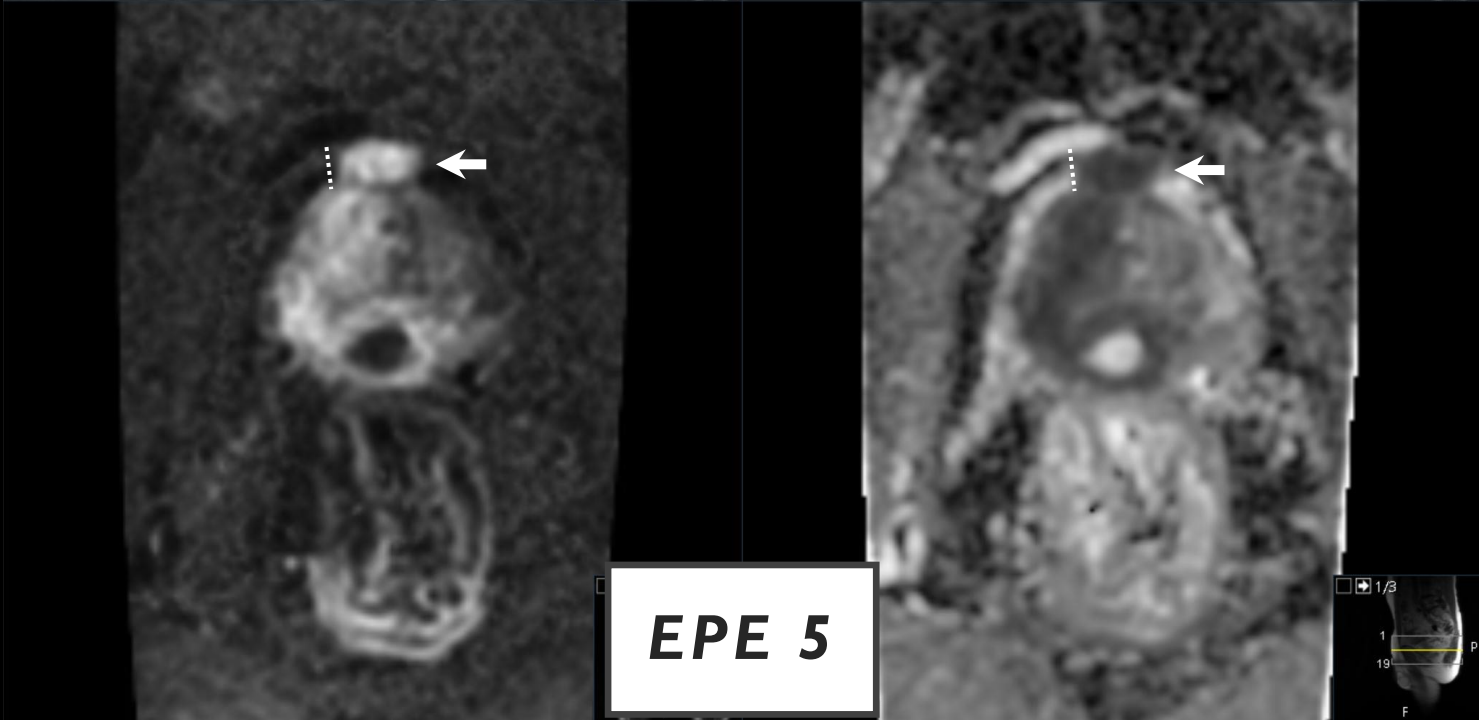
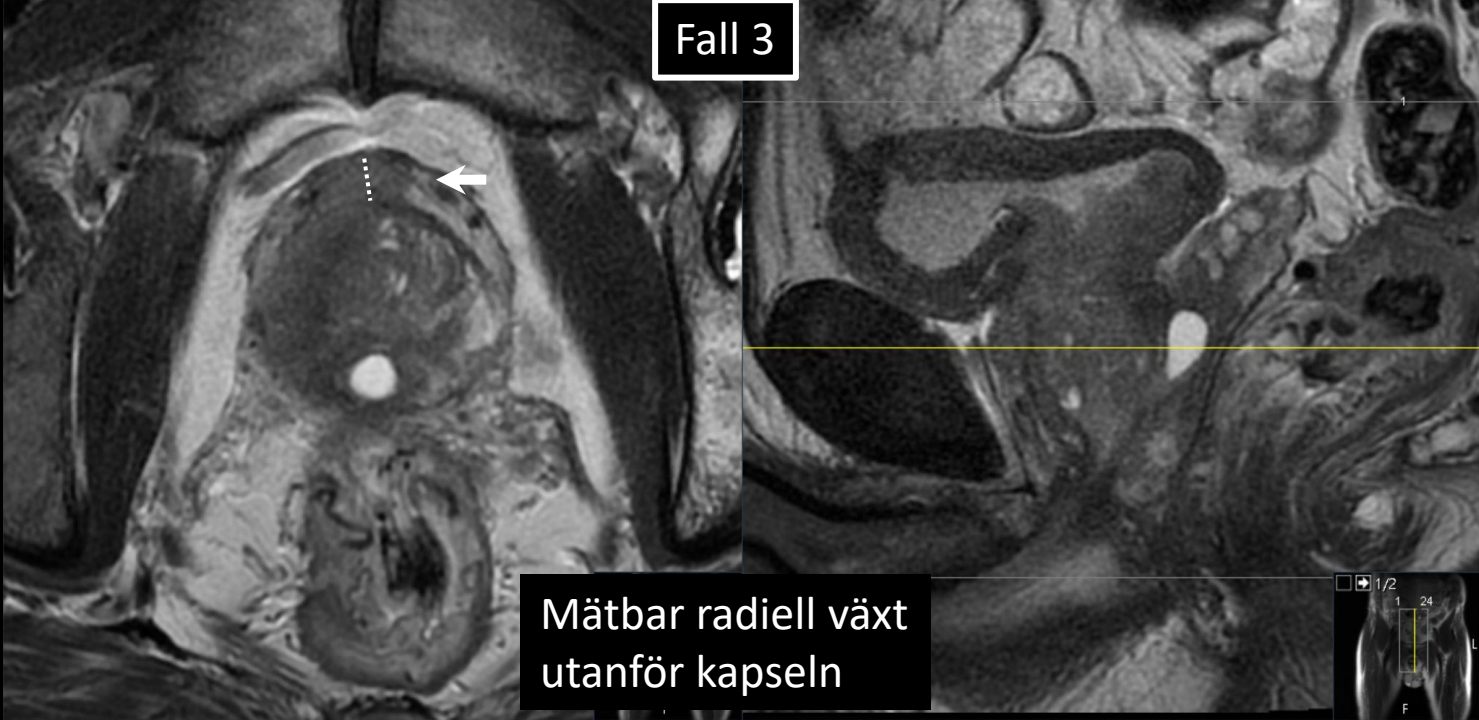
Mätbar radiell växt
utanför kapseln



EPE 5



Fall 3



STADIEINDELNING

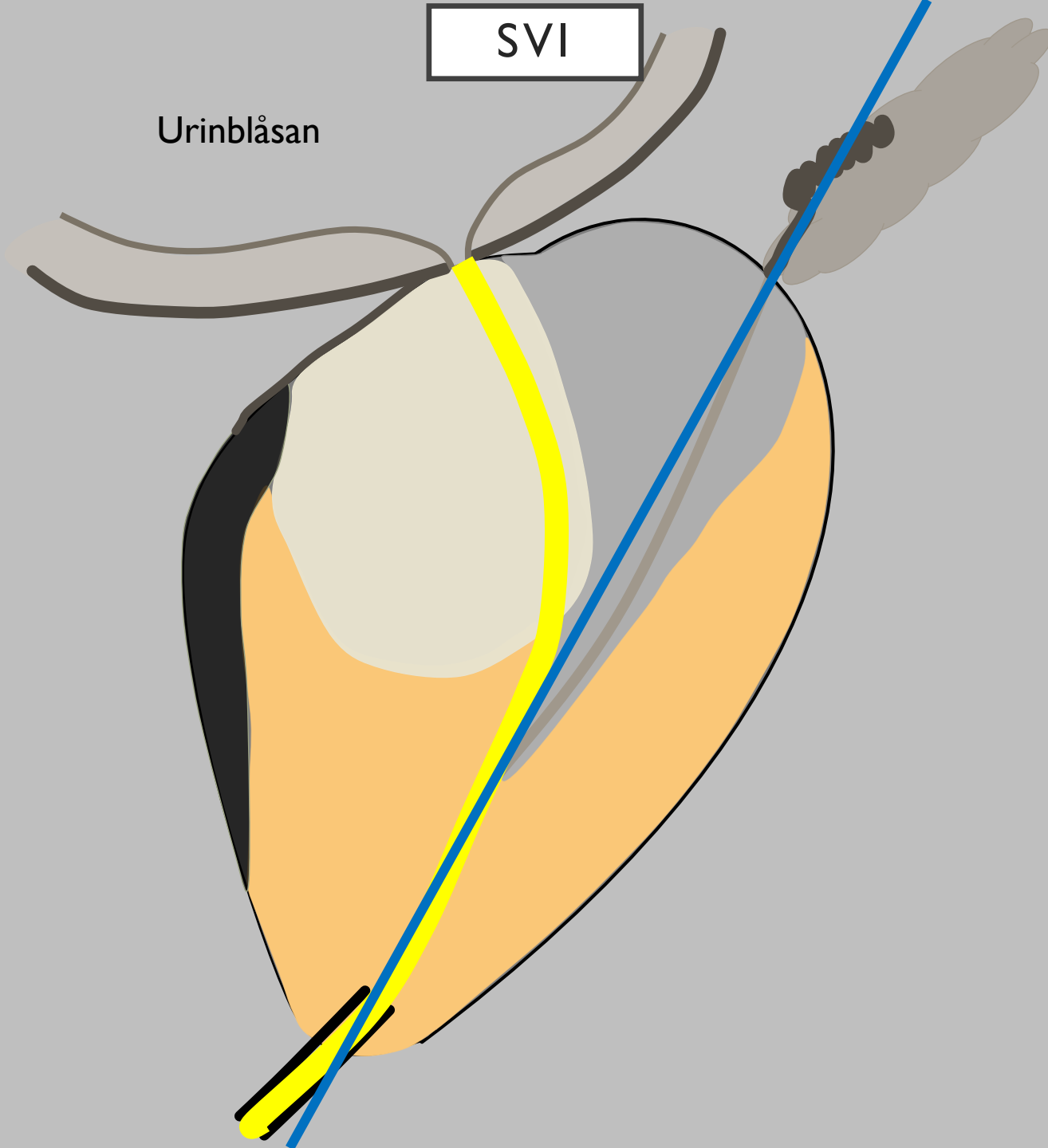
- LOKAL STADIEINDELNING
 - Extraprostatisk extension (EPE)
 - ***Seminalvesikel-invasjon (SVI)***
 - Nedre sfinkter (NS)
 - Blåshals

STADIEINDELNING

- LOKAL STADIEINDELNING
 - ***Seminalvesikel-invasion (SVI)***
 - ***4 olika spridningsvägar***

SVI

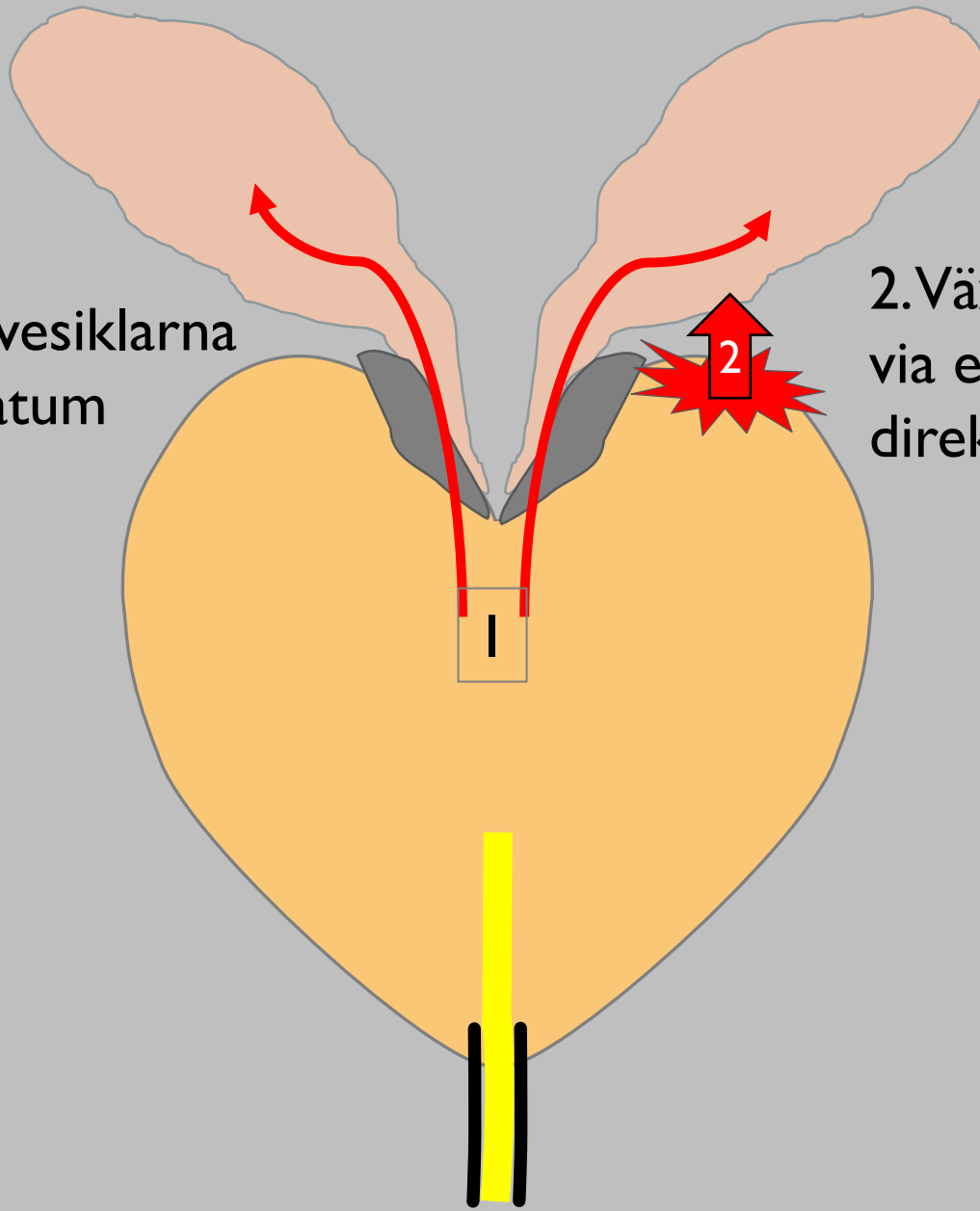
Urinblåsan



SEMINAL VESIKELINVASION (SVI)

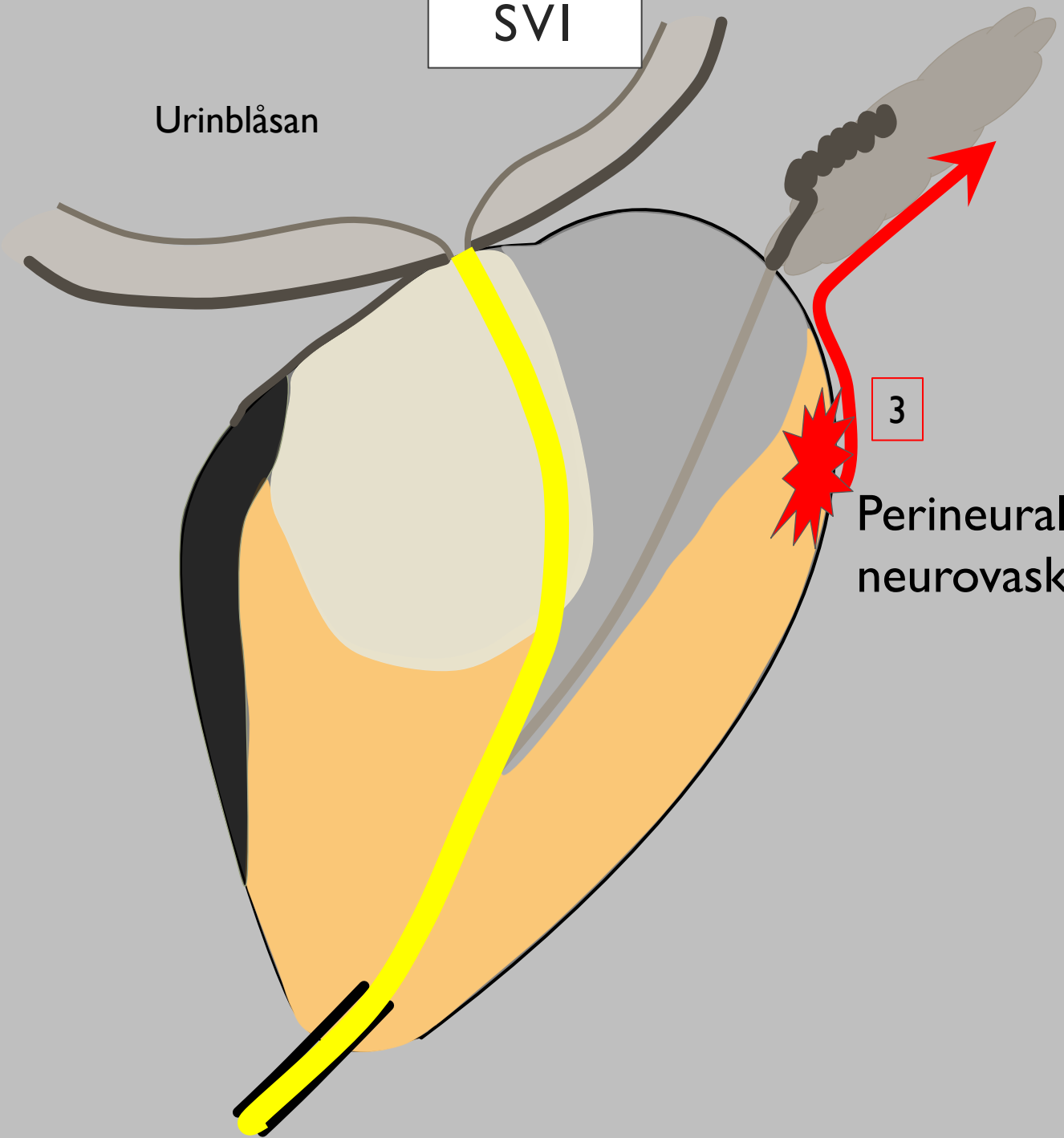
1. Växt upp i vesiklarna
perkontinuitatum

2. Växt upp i vesiklarna
via extraprostatisk
direktöverväxt.



SVI

Urinblåsan



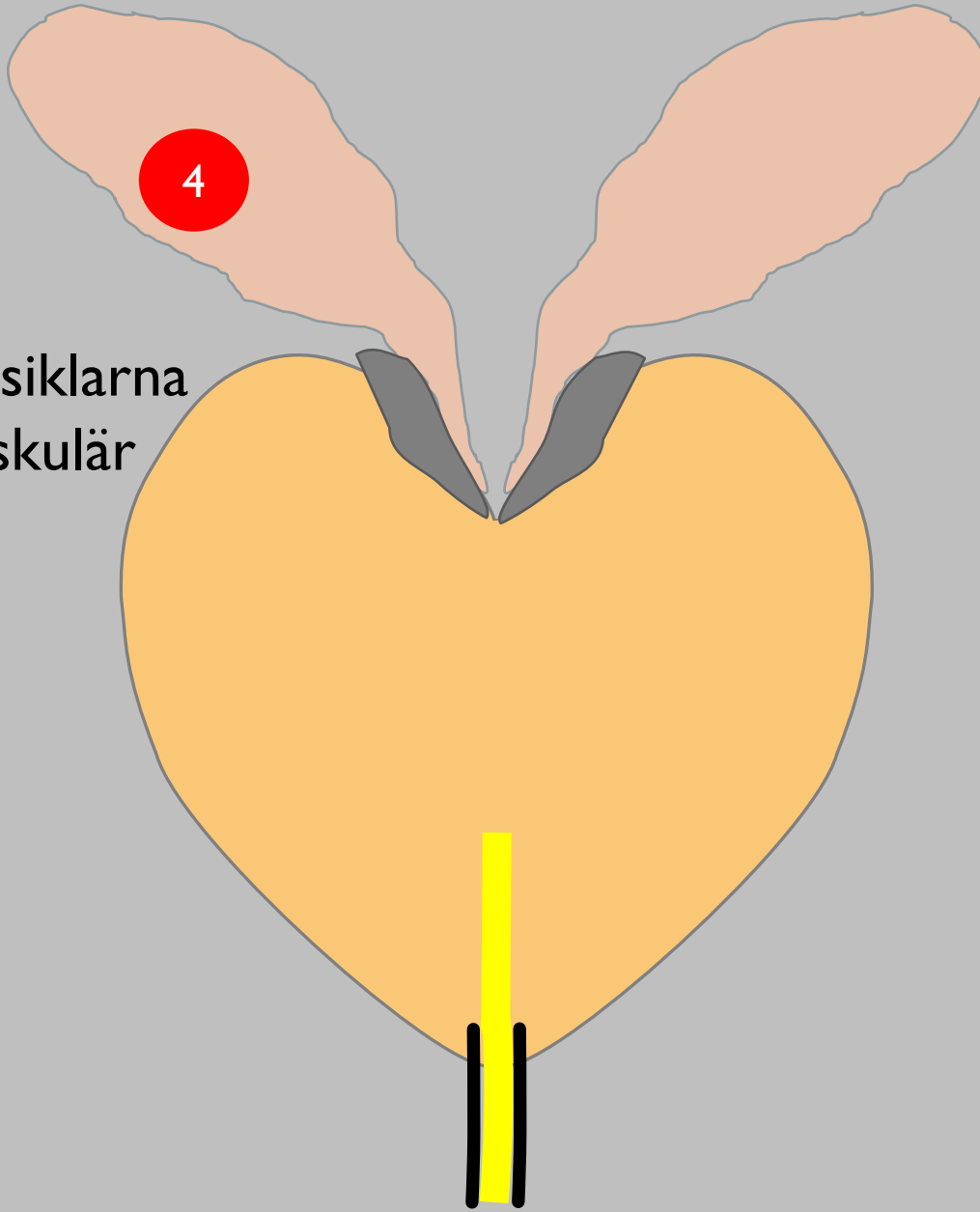
3

Perineural växt utmed neurovaskulära buntar

SVI

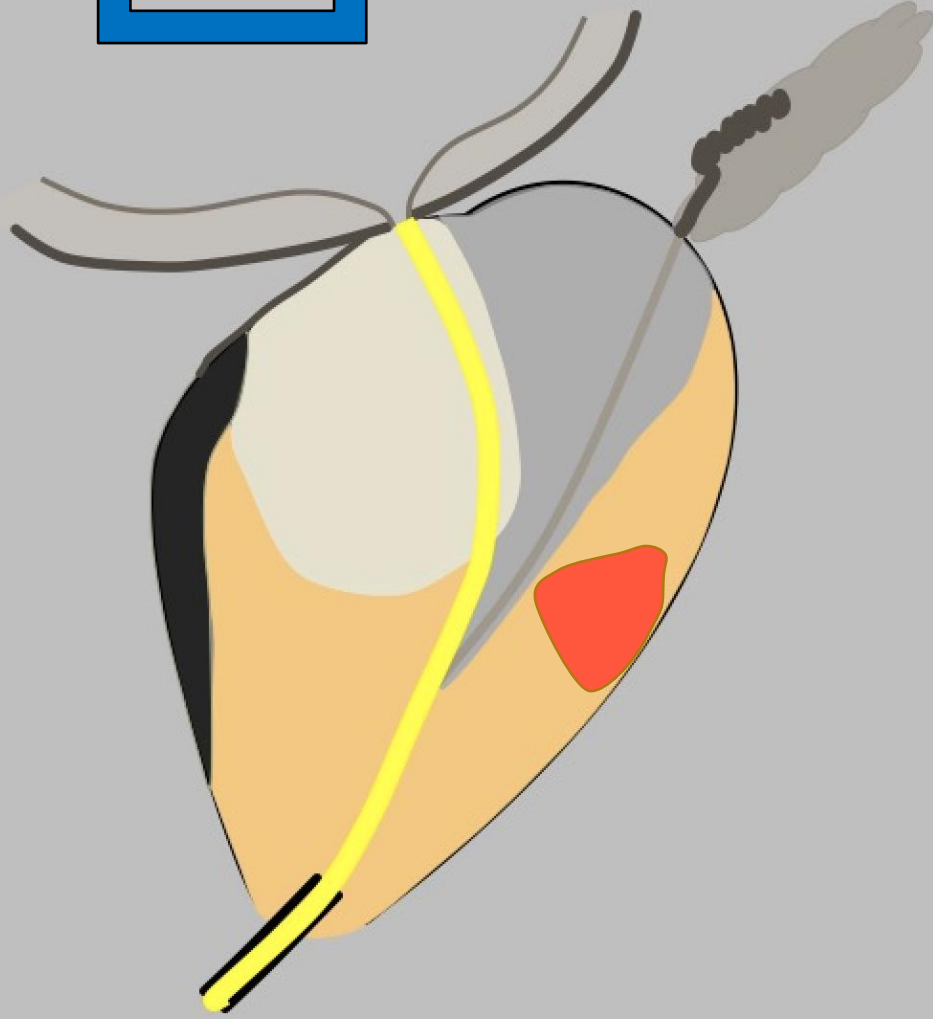


4

“Skip-lesion”
metastaser i vesiklarna
- lymfogen/vaskulär
spridning



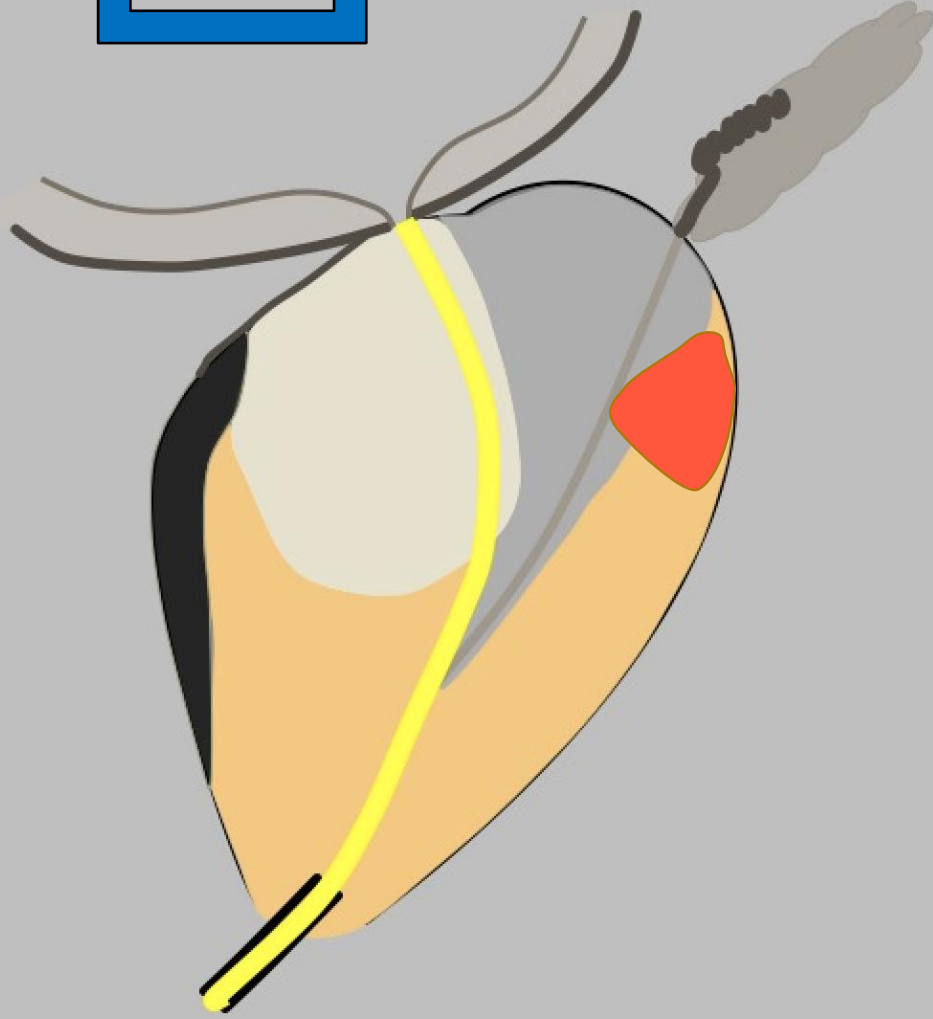
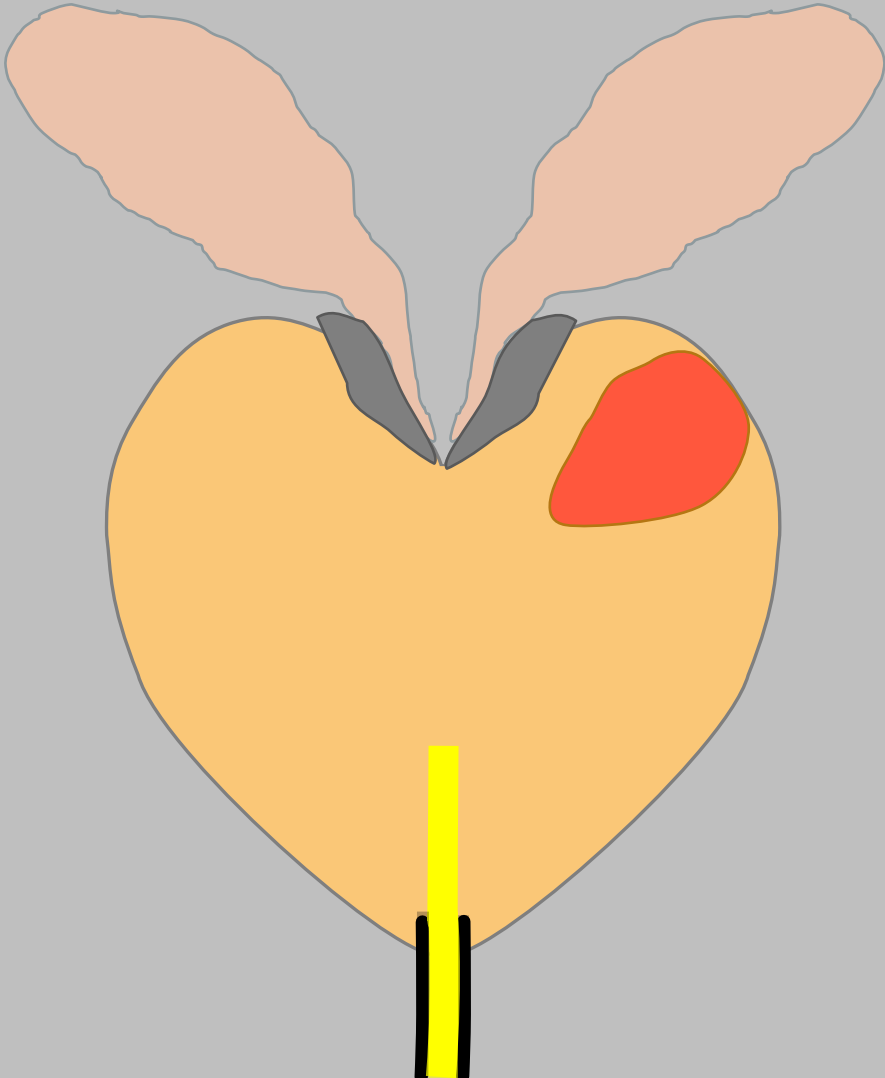

SEMINALVESIKEL-INVASION (SVI)

SVI I



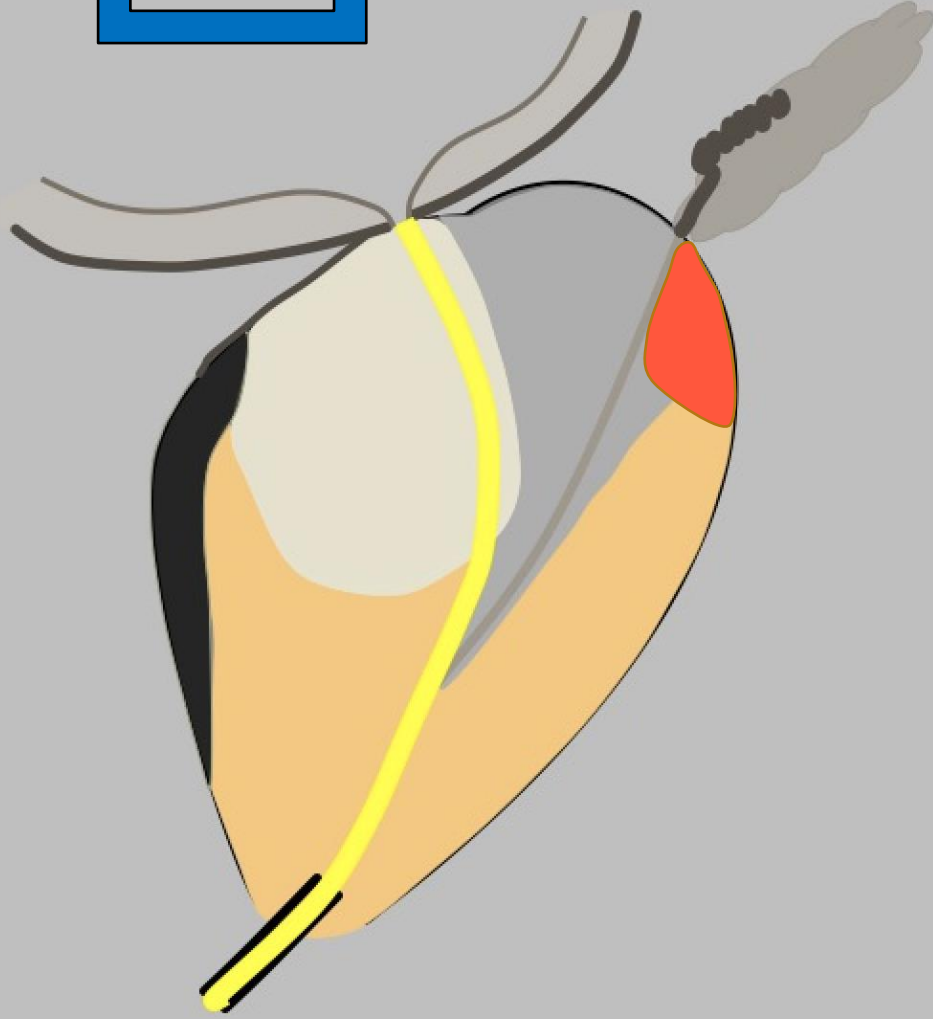
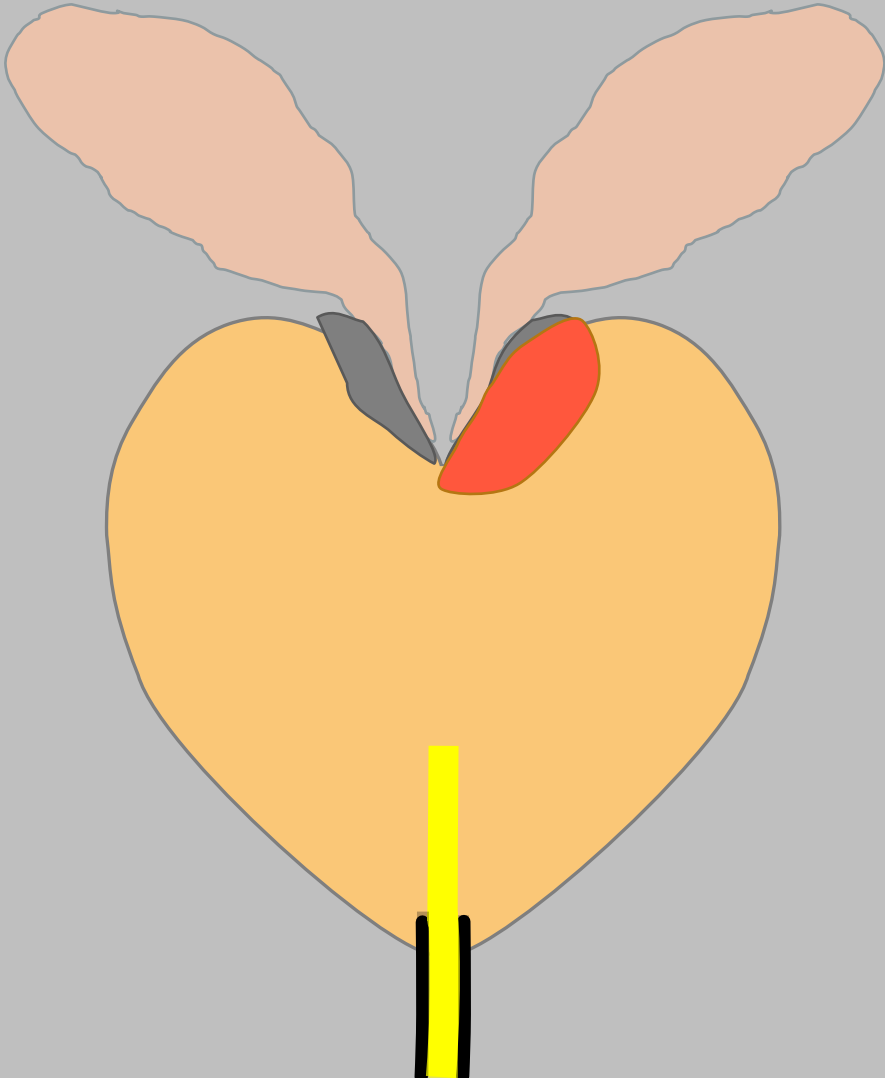

SEMINAL VESIKELINVASION (SVI)

SVI 2

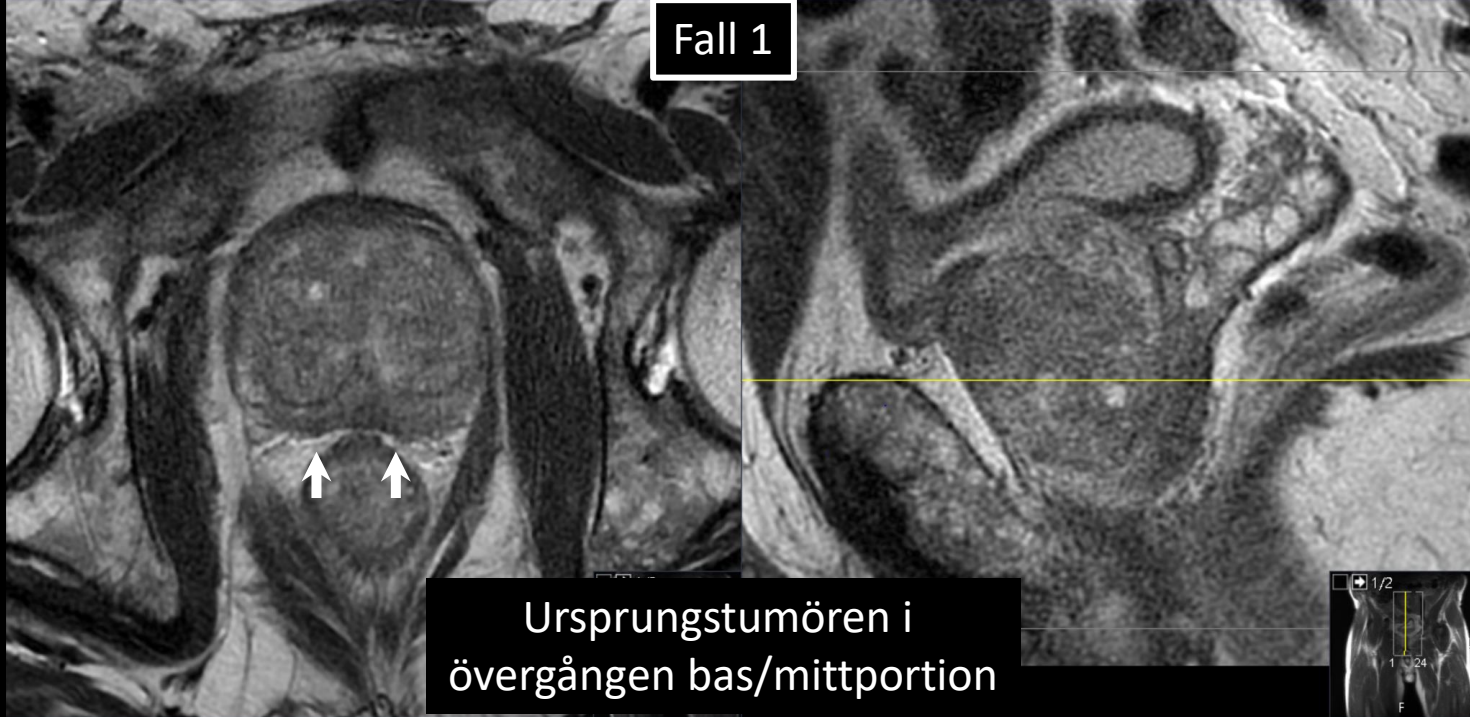


SEMINAL VESIKELINVASION (SVI)

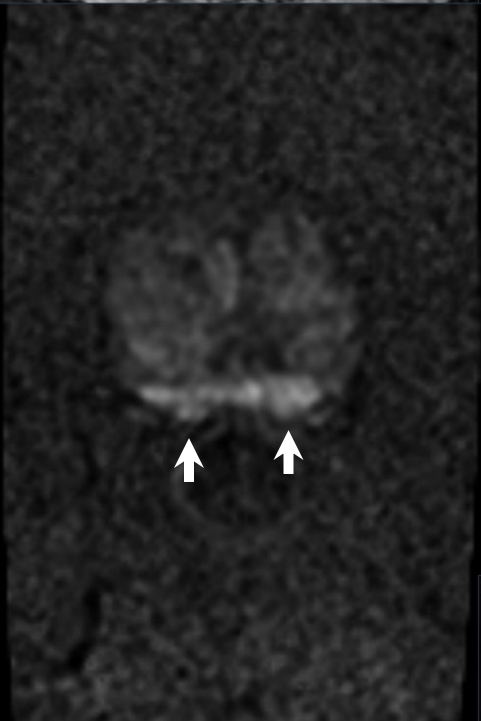
SVI 3



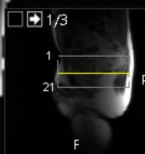
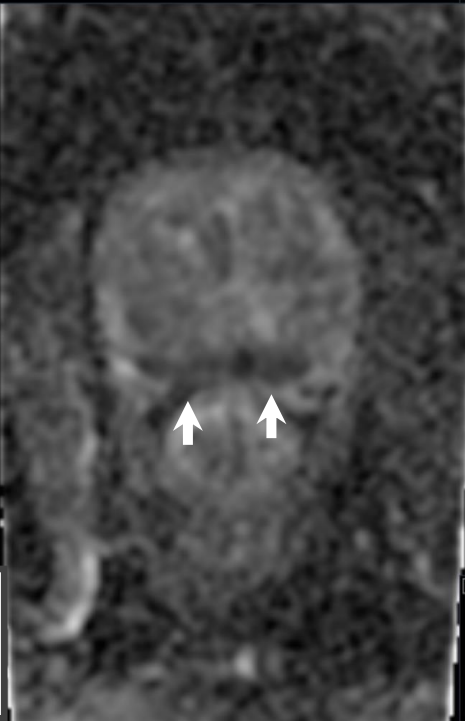
Fall 1



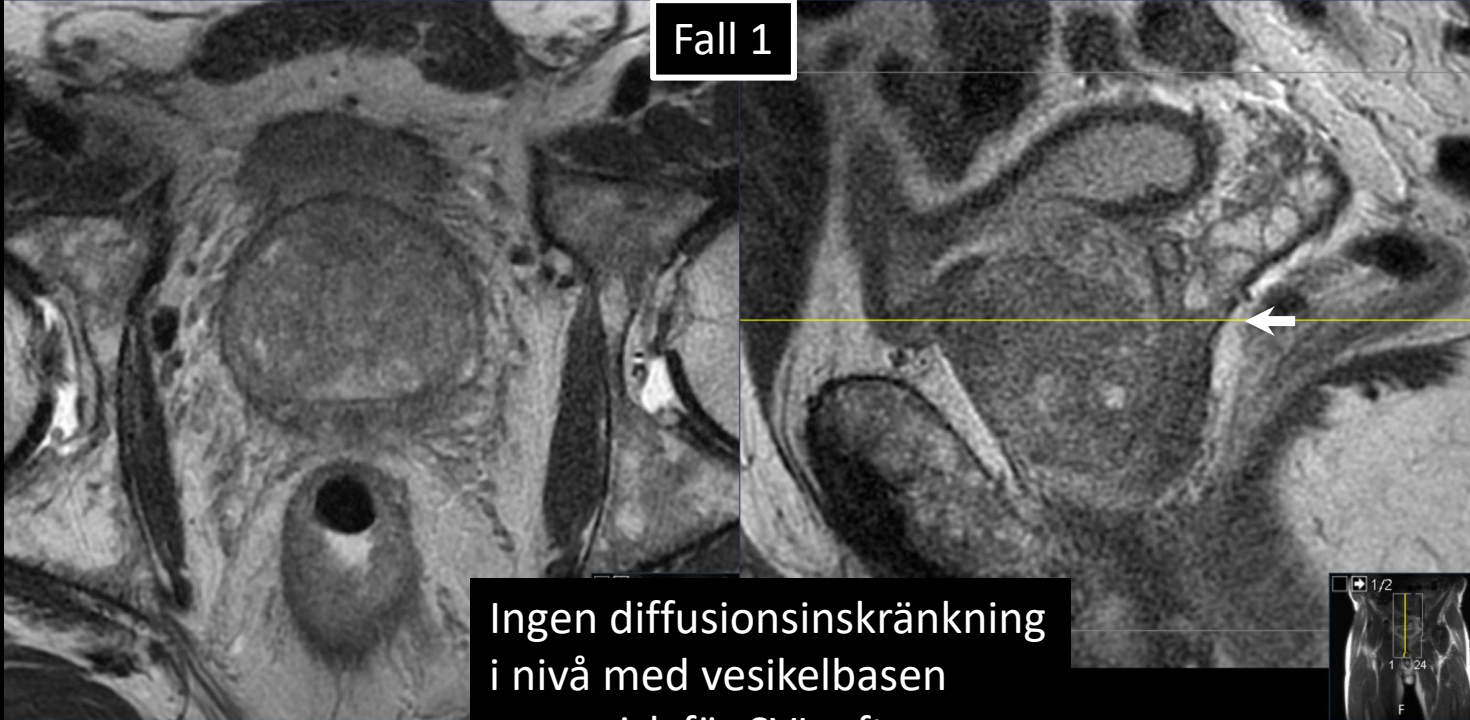Ursprungstumören i övergången bas/mittportion



SVI 3

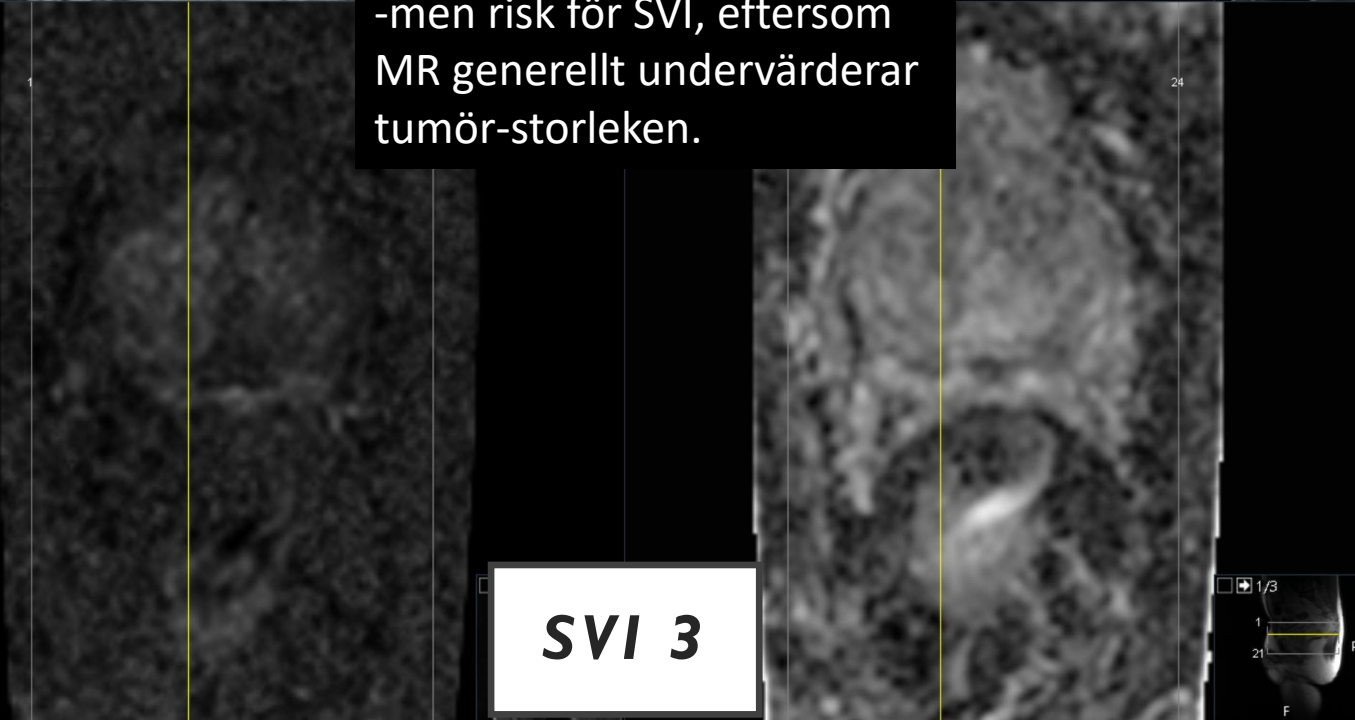


Fall 1



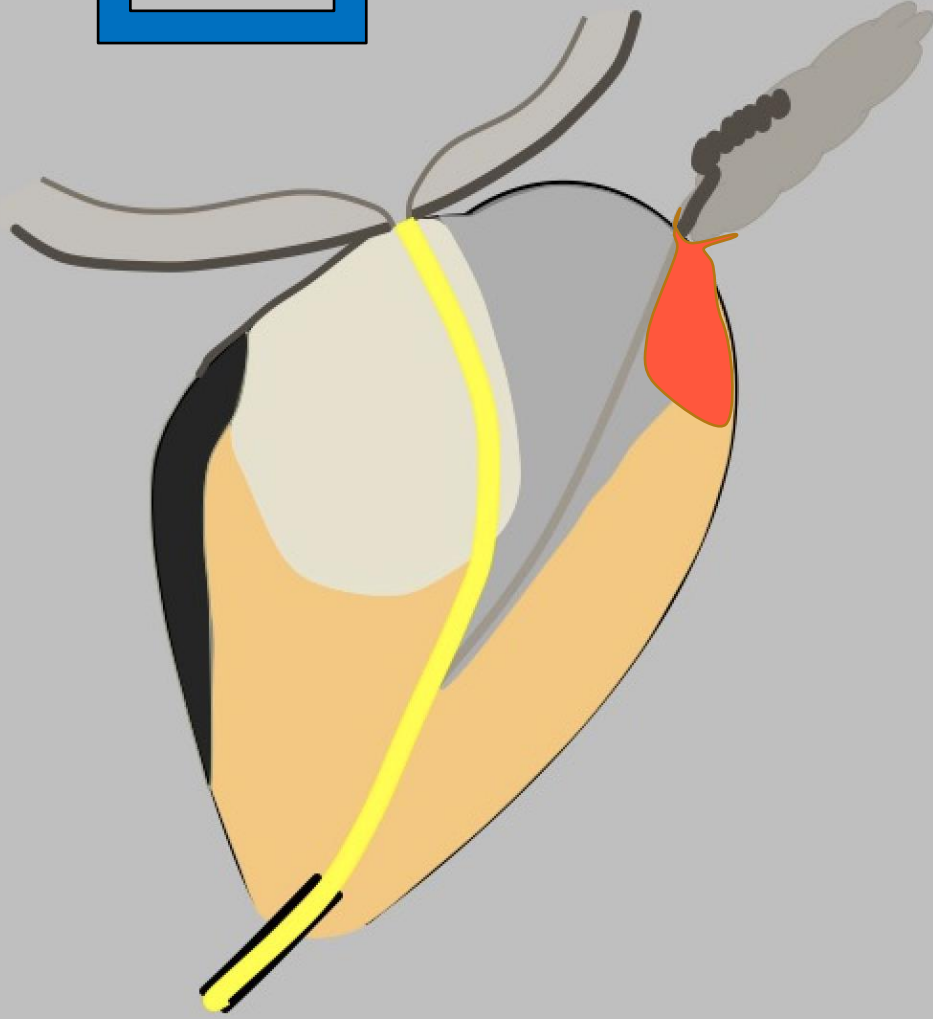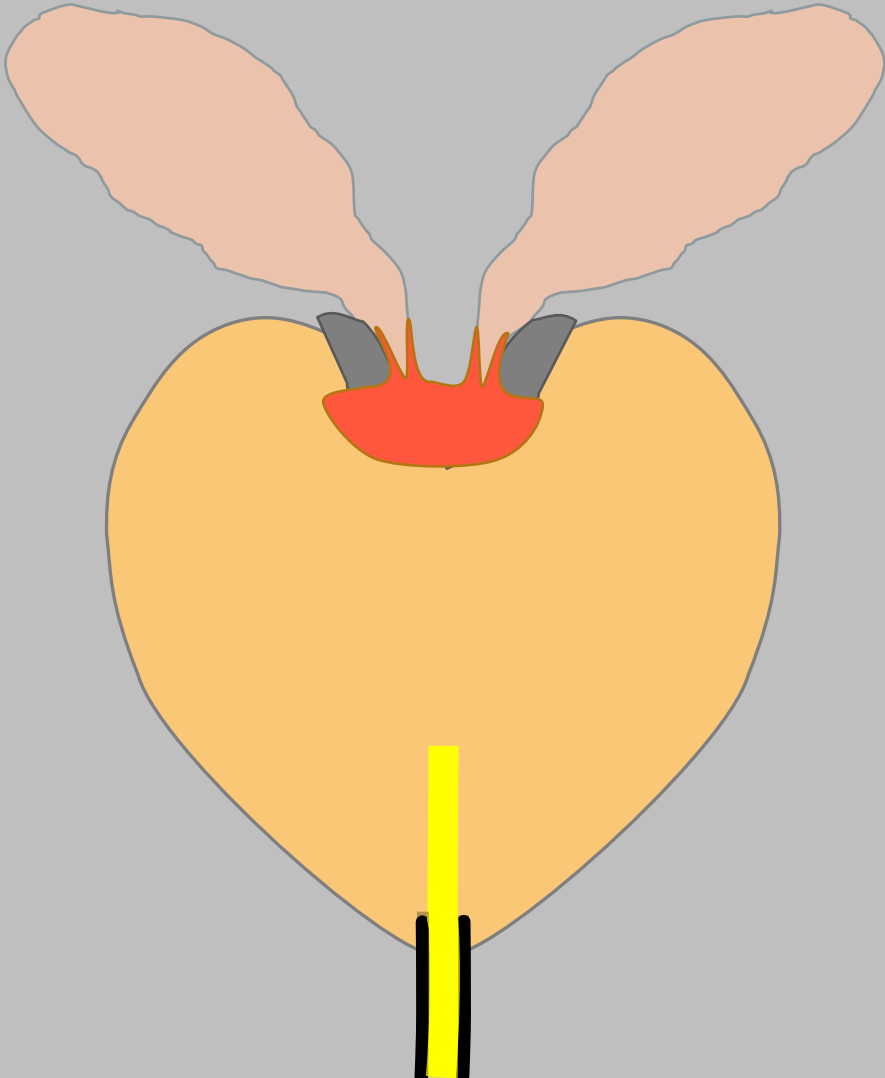

Ingen diffusionsinskränkning
i nivå med vesikelbasen
-men risk för SVI, eftersom
MR generellt undervärderar
tumör-storleken.

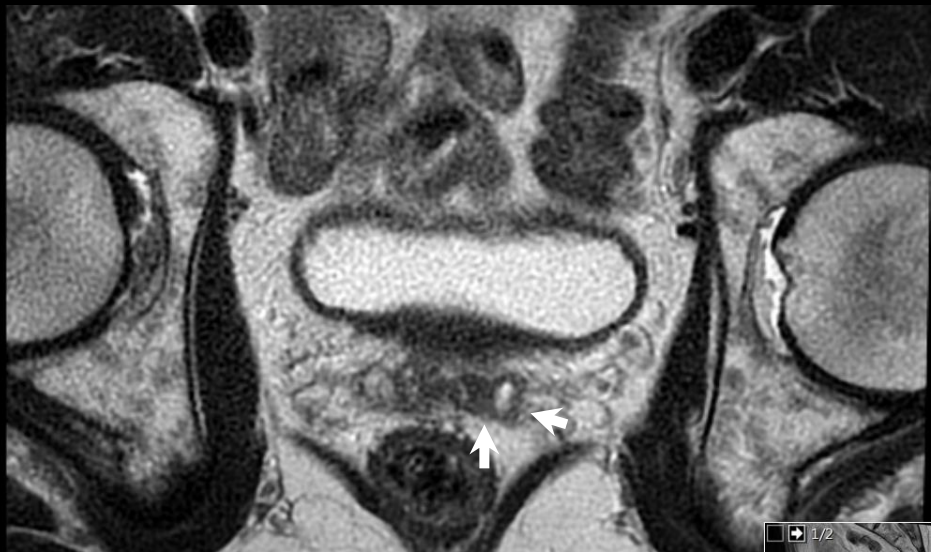SVI 3



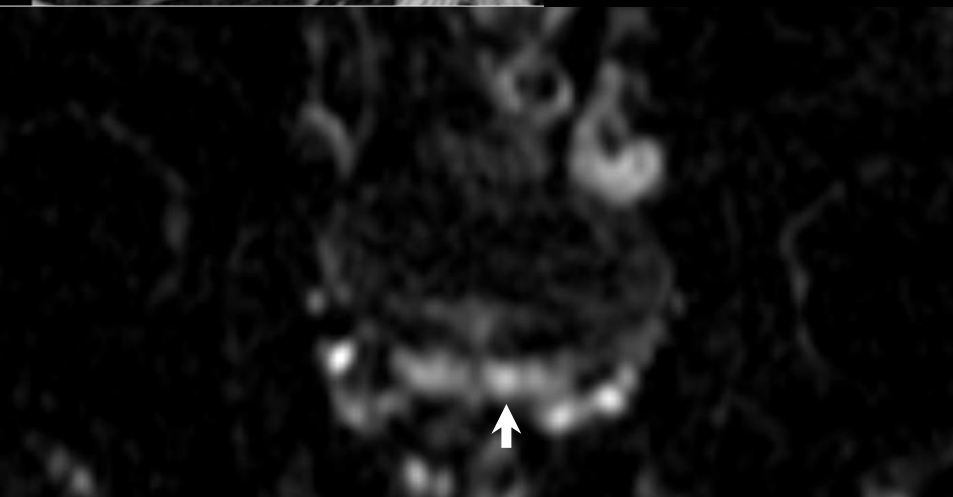
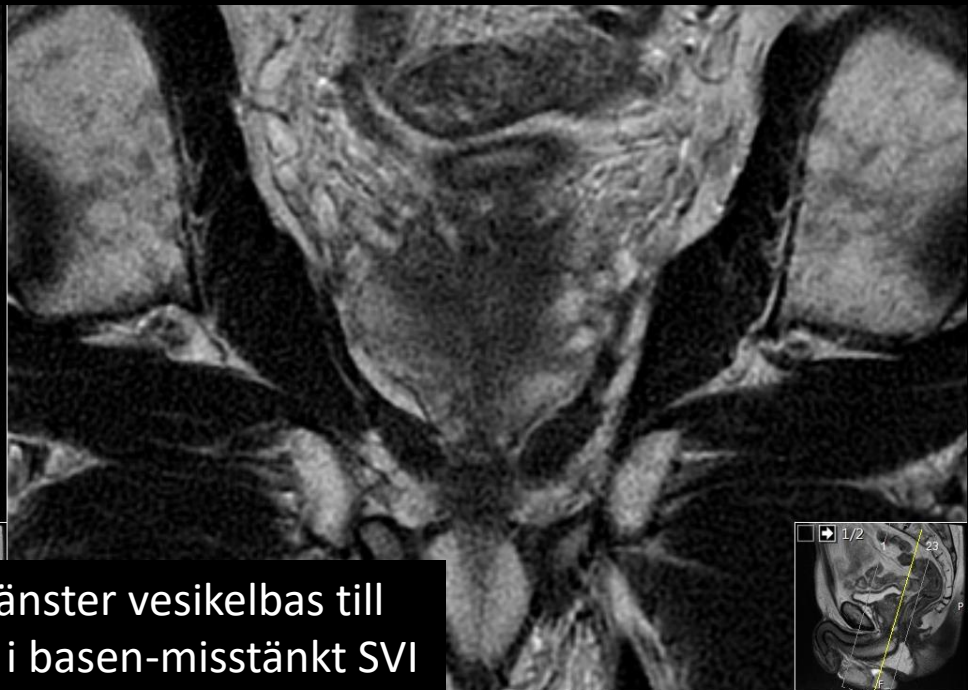SEMINAL VESIKELINVASION (SVI)

SVI 4

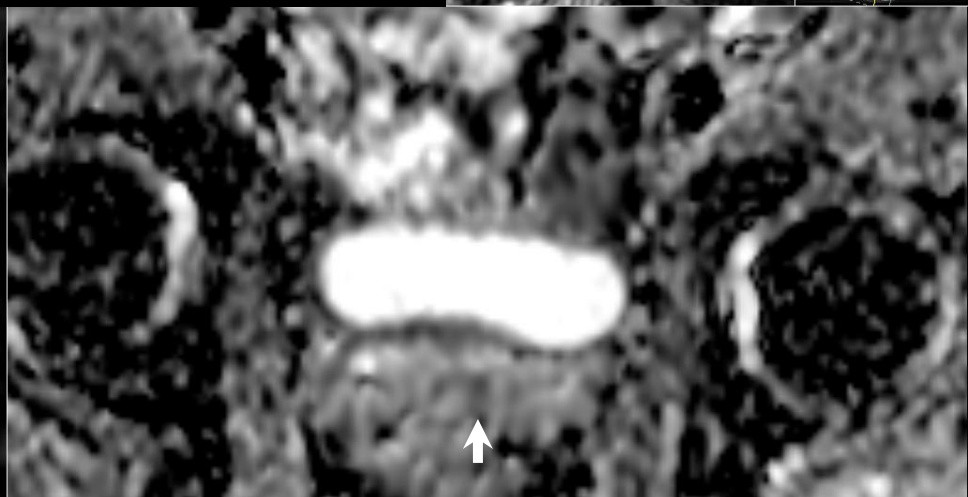




Förtjockning kring vänster vesikelbas till angränsande tumör i basen-misstänkt SVI



Diffusionsinskränkning i vesikelbasen -misstänkt SVI

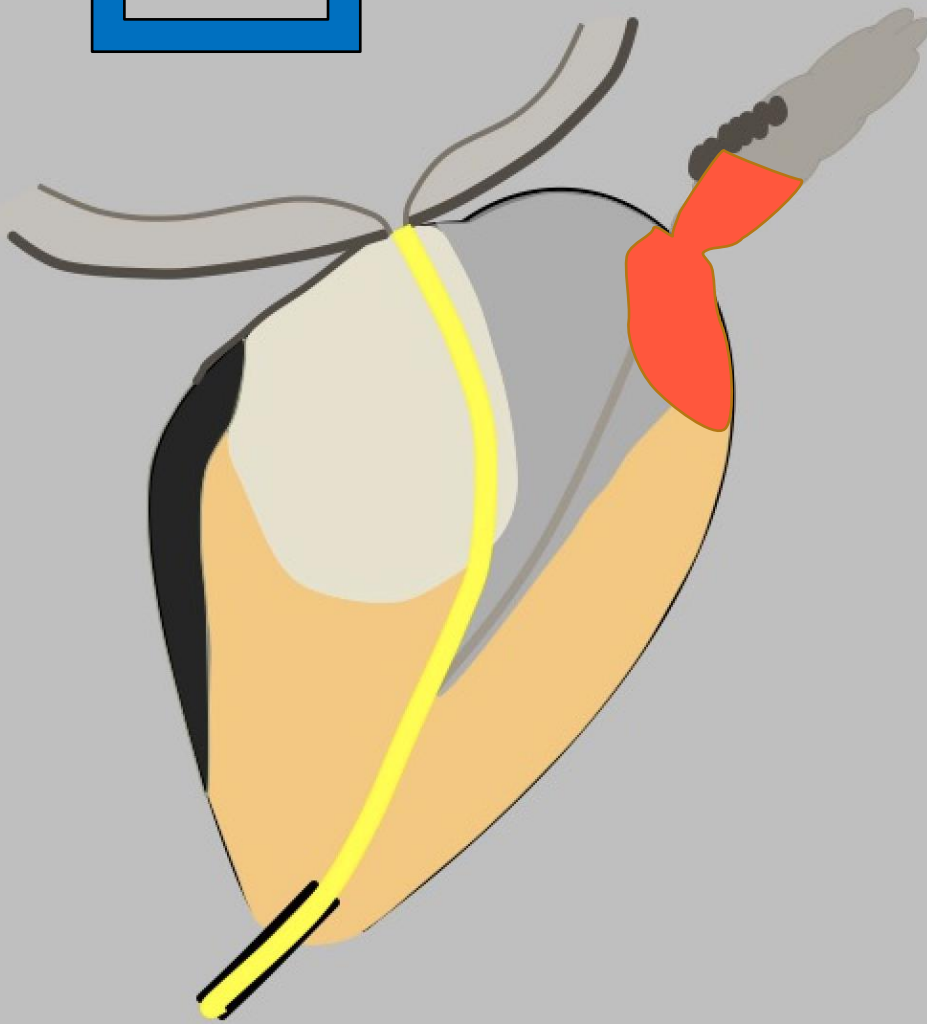
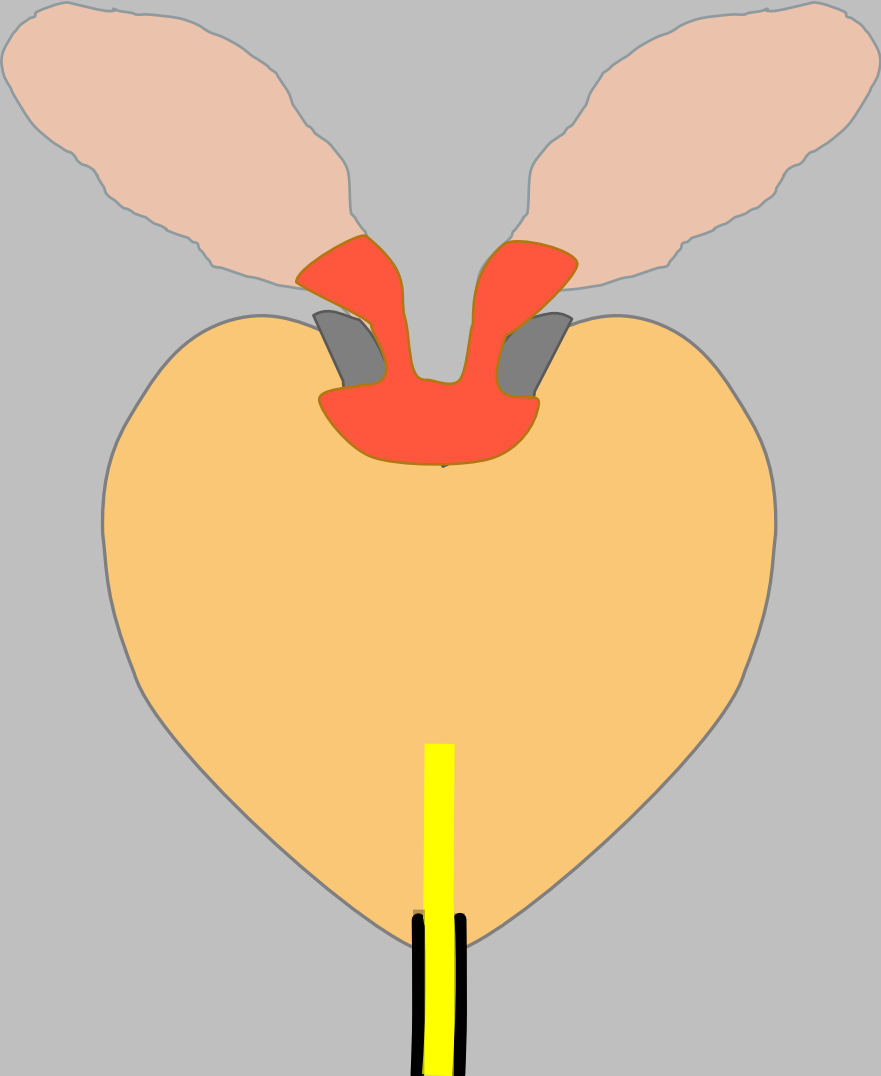



Diffusionsinskränkning i vesikelbasen -misstänkt SVI

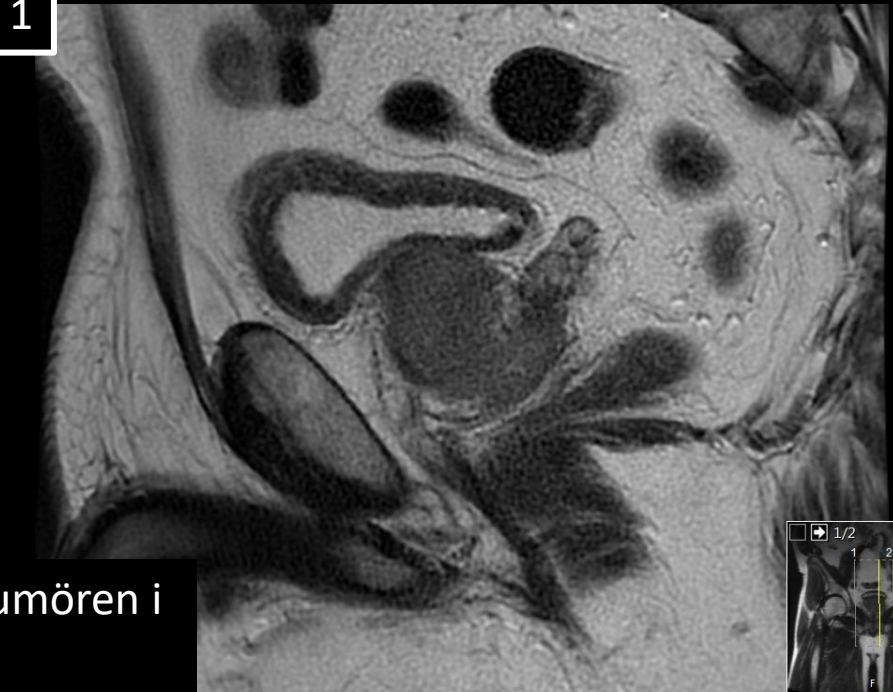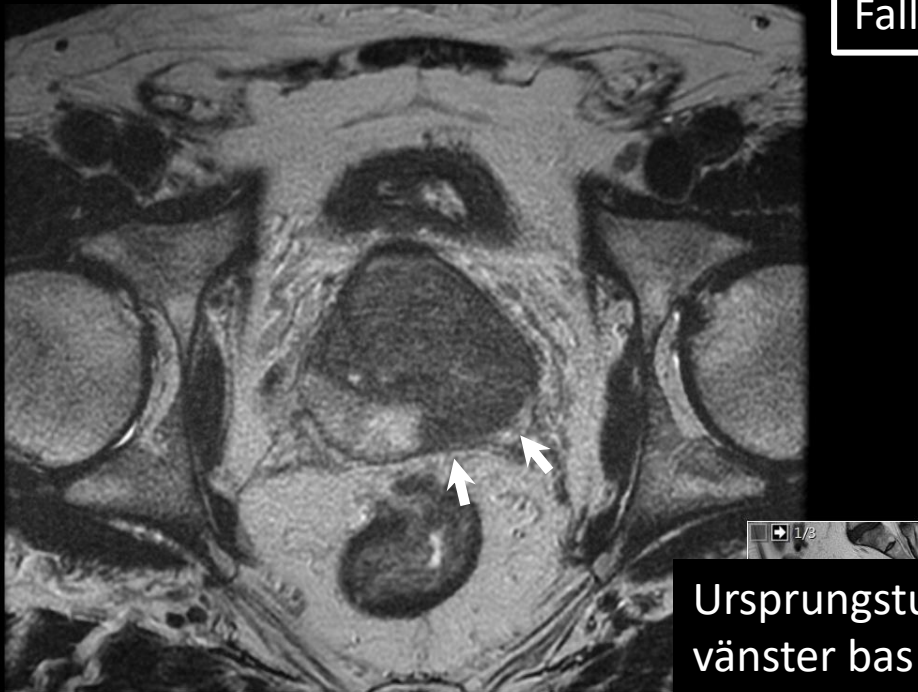
SVI 4

SEMINAL VESIKELINVASION (SVI)

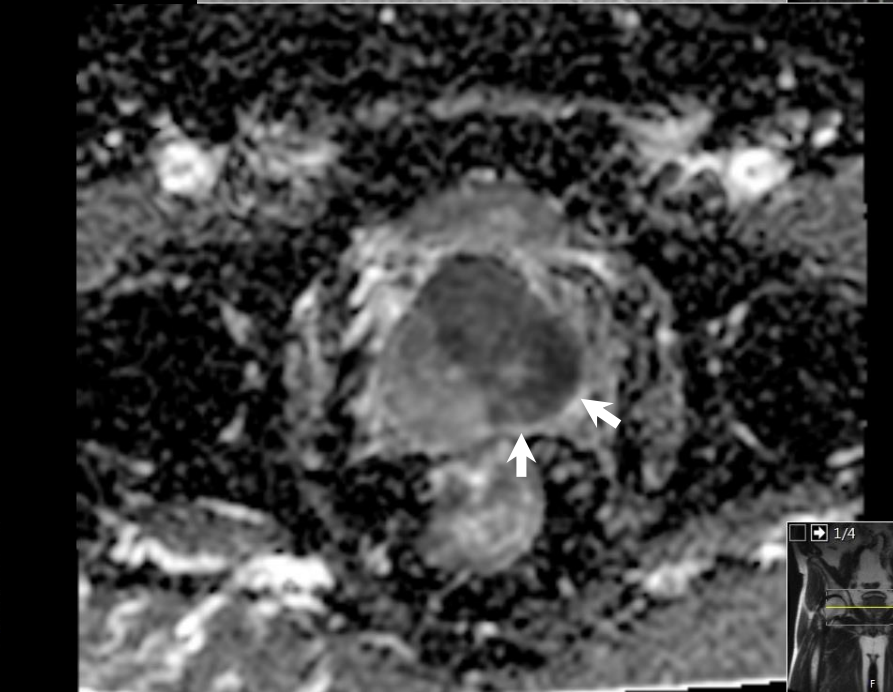
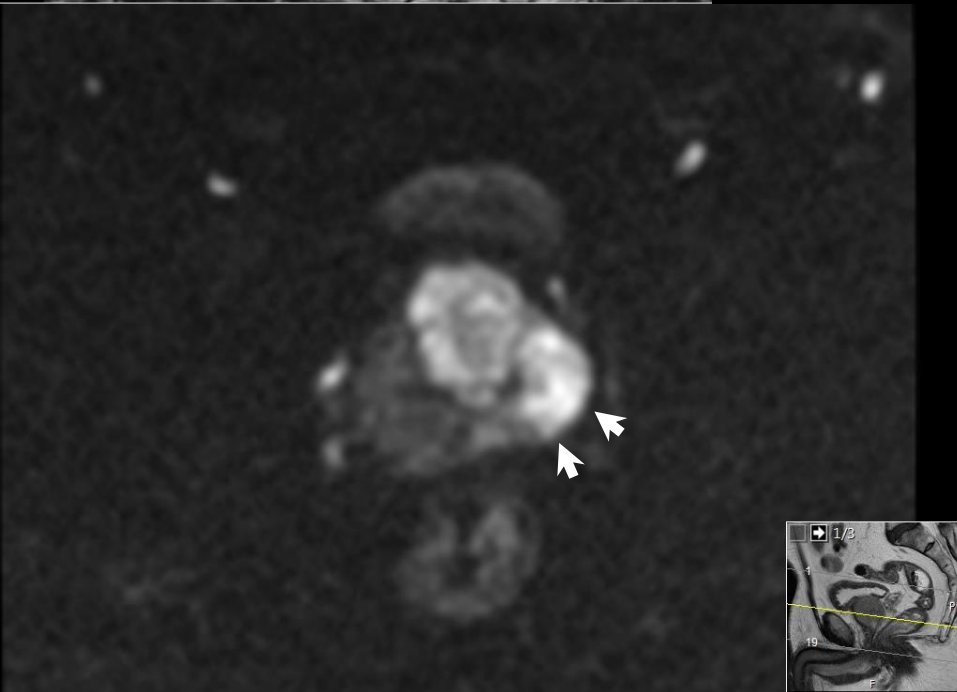
SVI 5



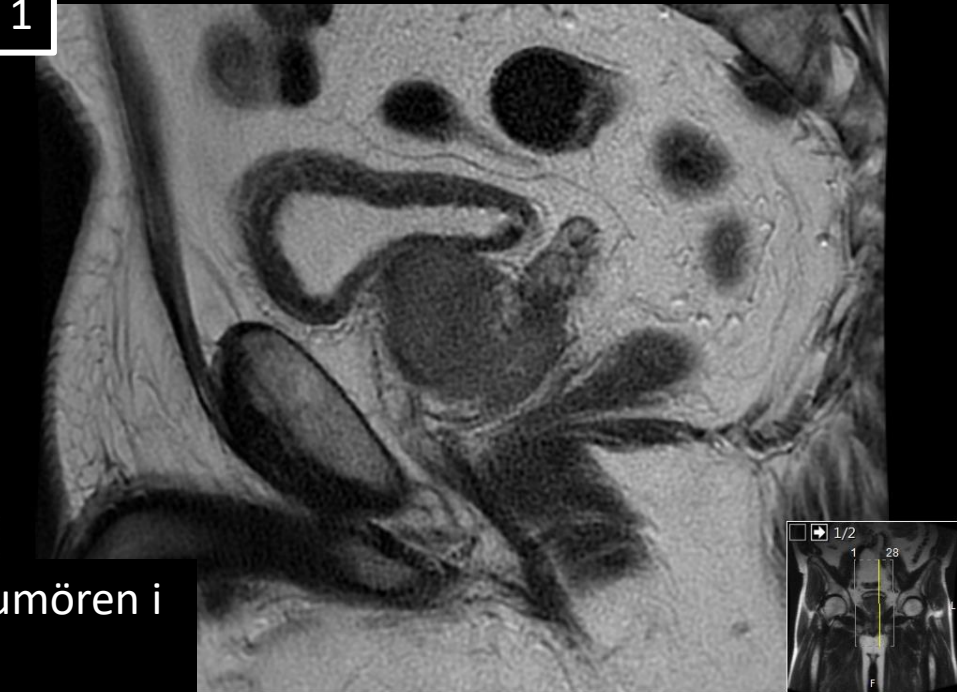
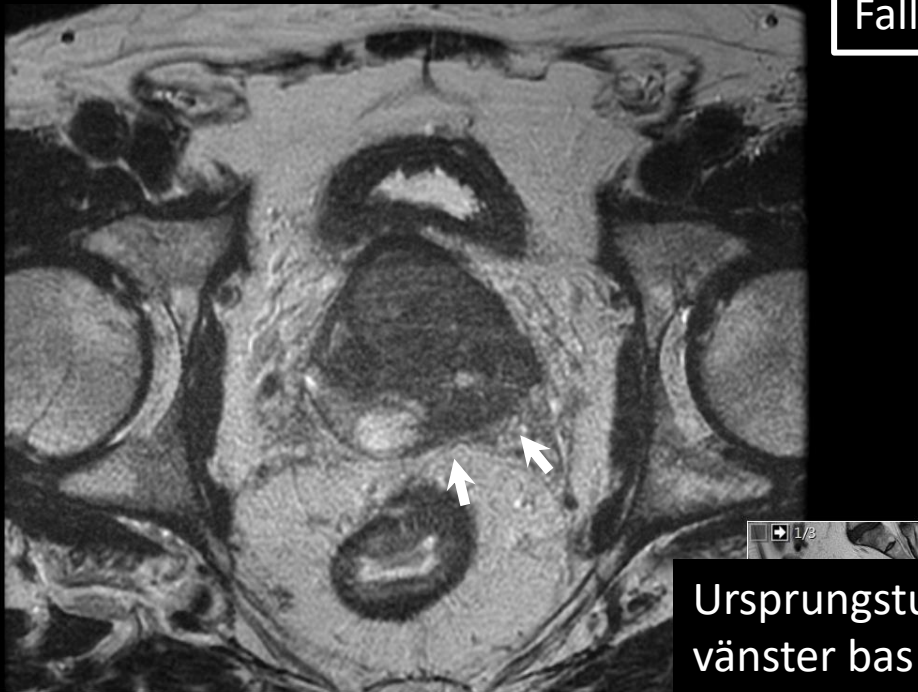
Fall 1



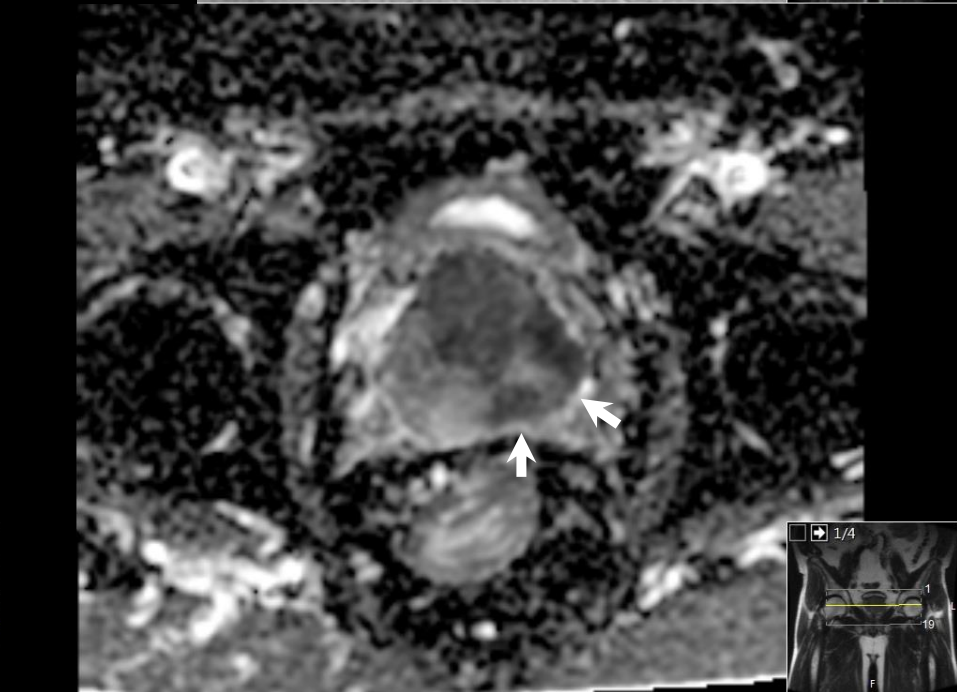
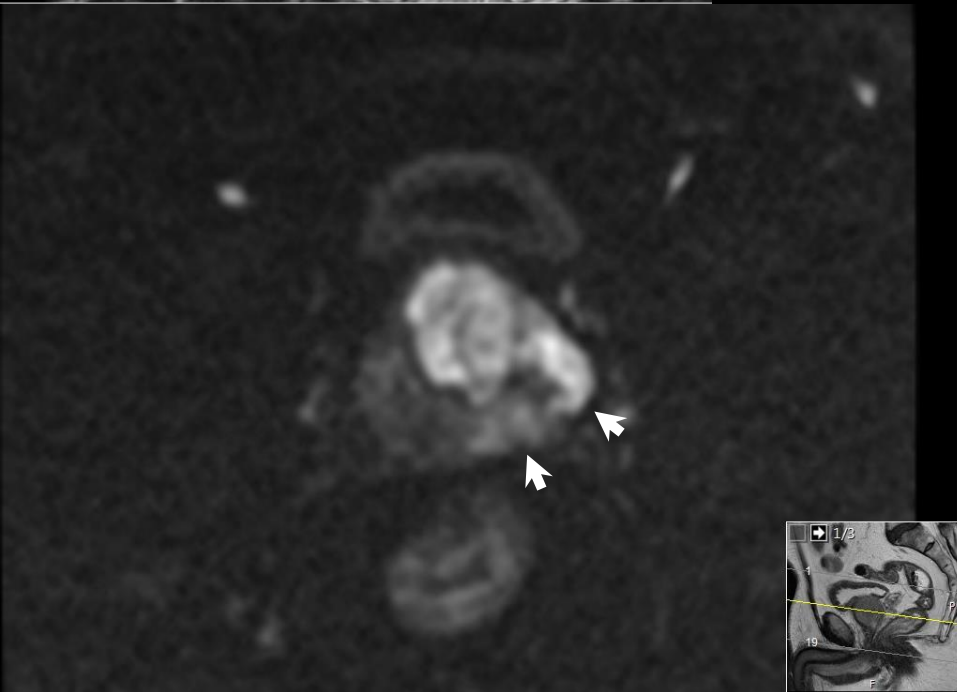
Ursprungstumören i vänster bas



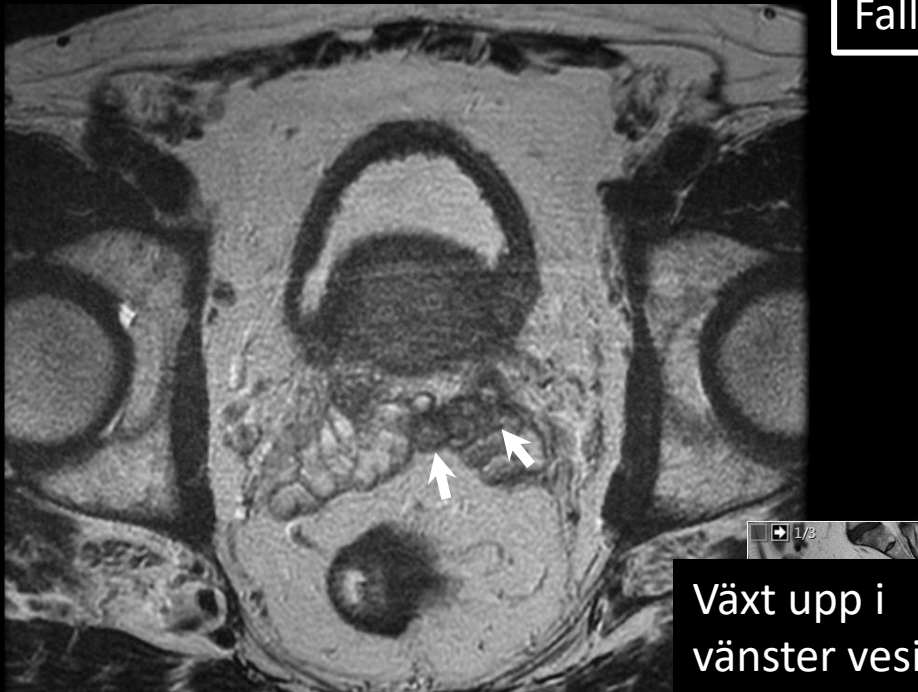
Fall 1



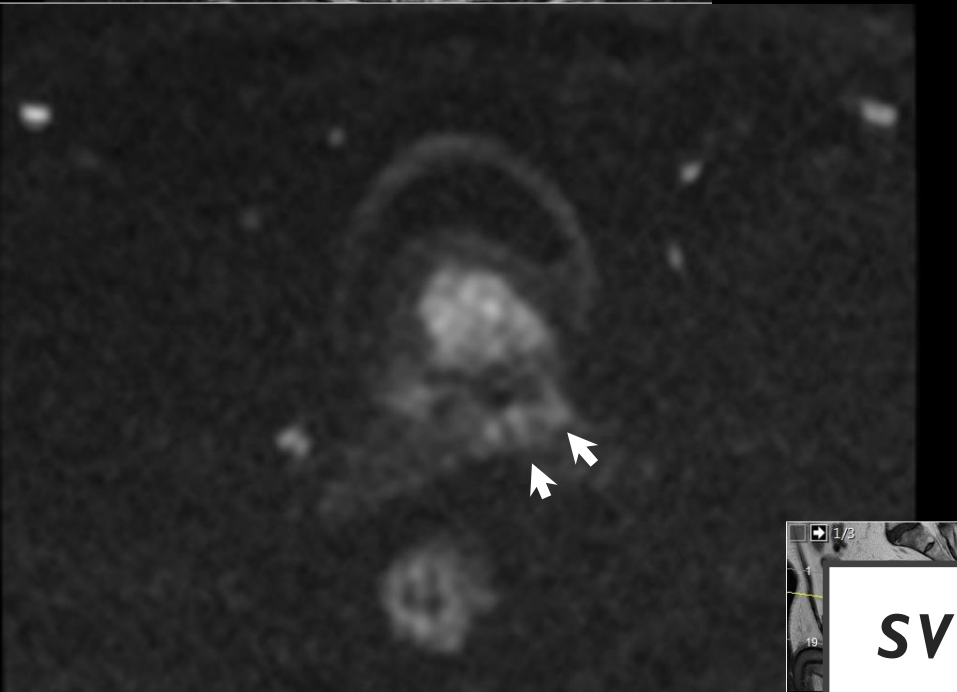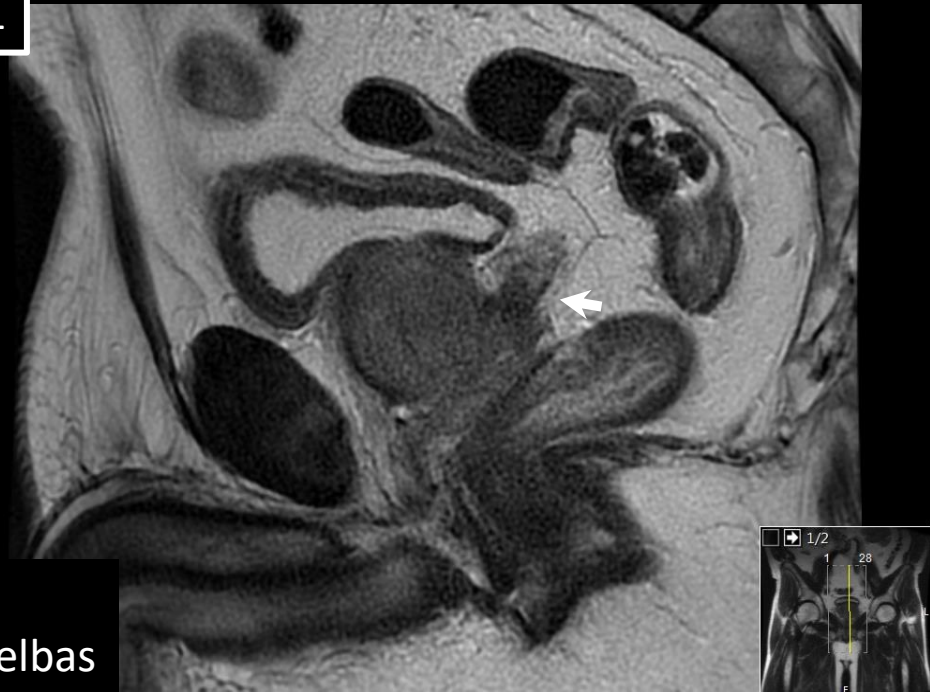
Ursprungstumören i vänster bas



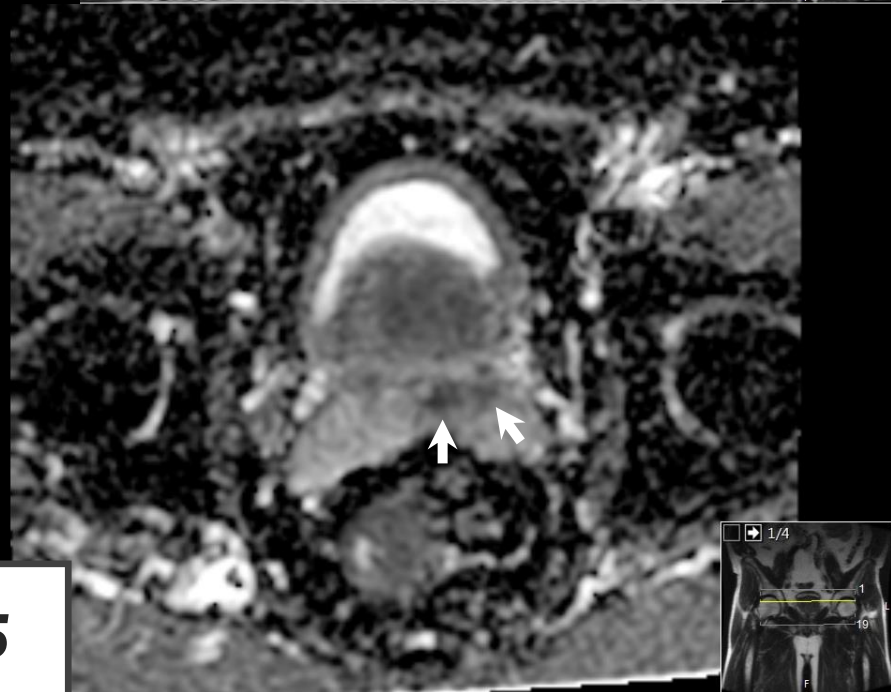
Fall 1



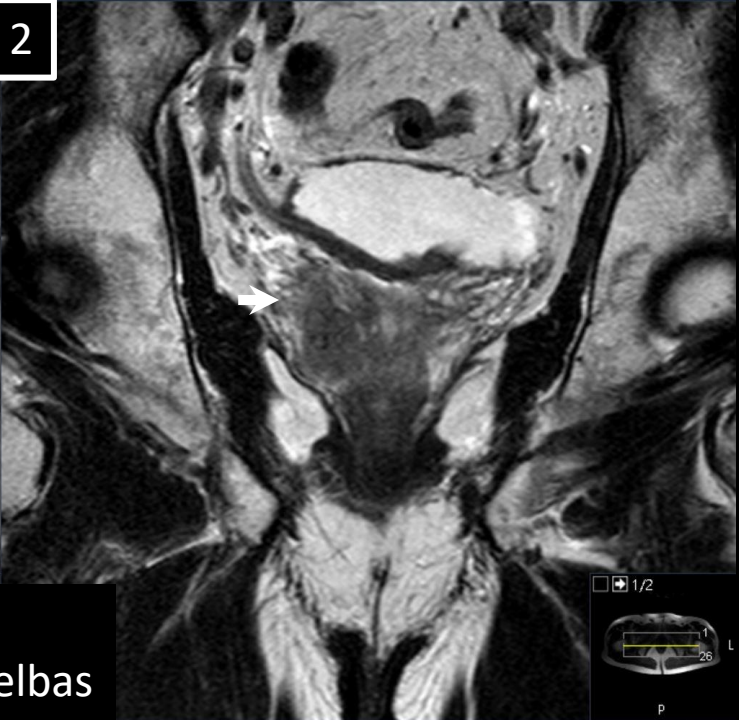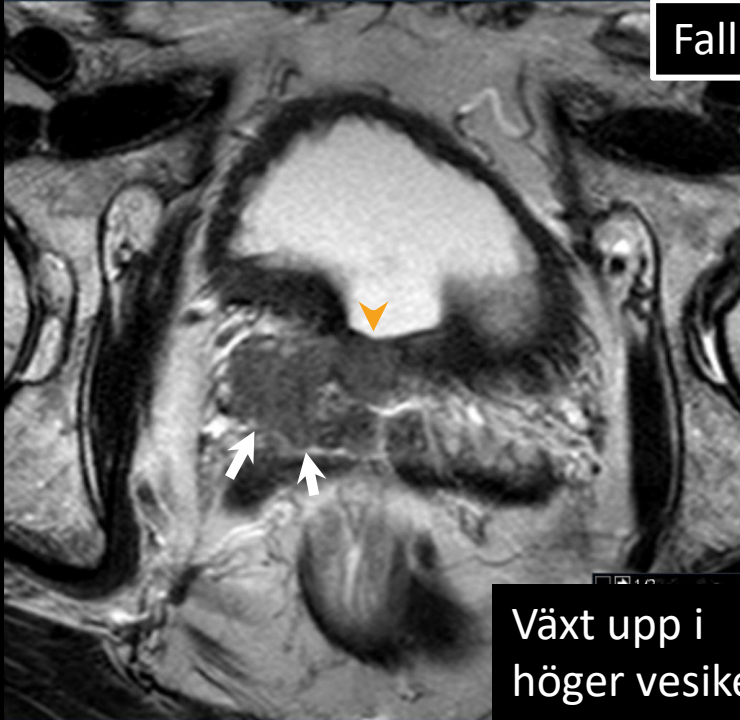
Växt upp i vänster vesikelbas



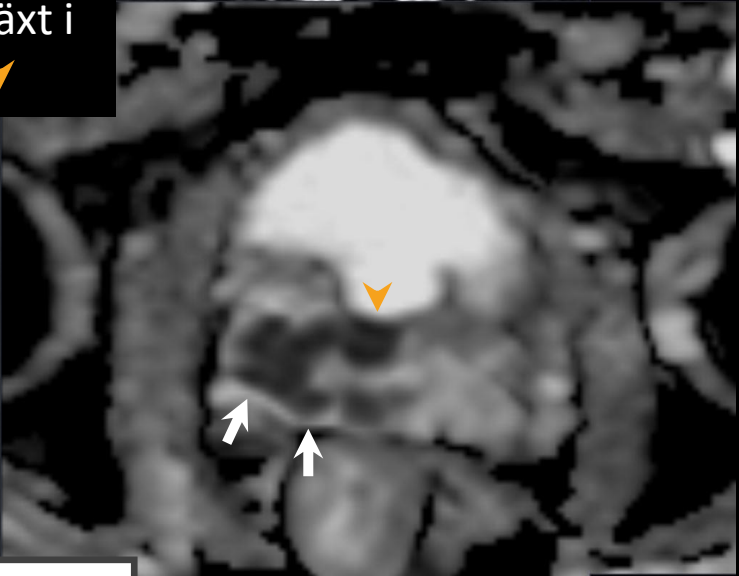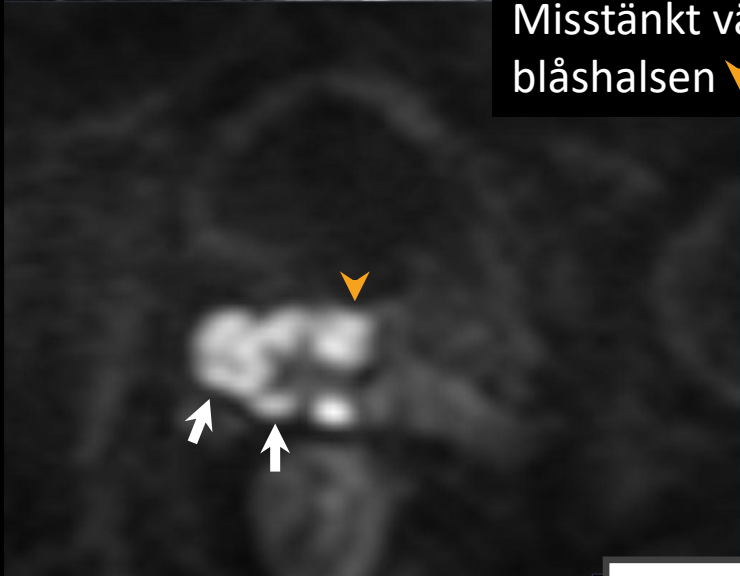SVI 5



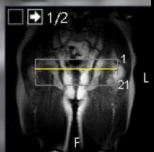
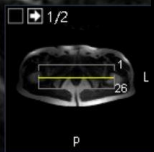
Fall 2



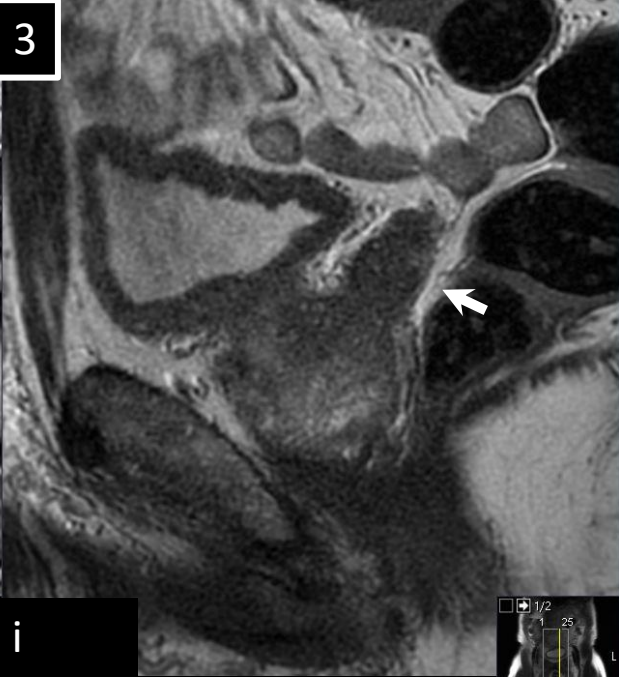
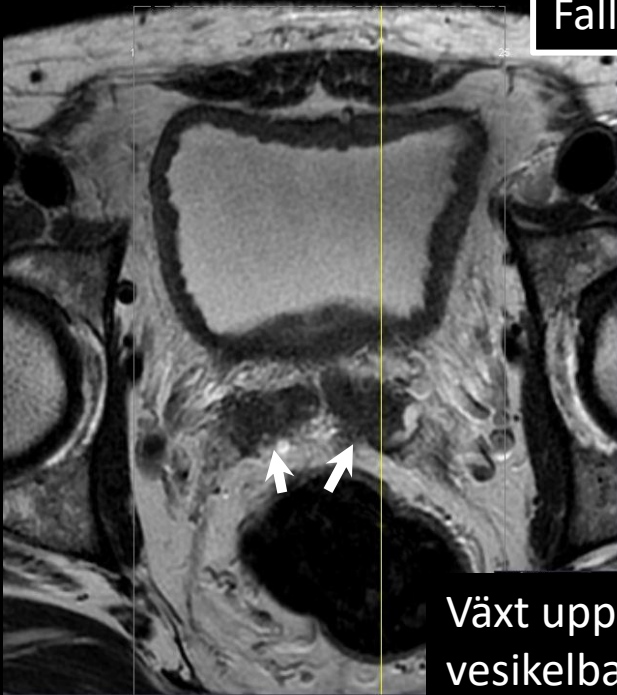
Växt upp i
höger vesikelbas
Misstänkt växt i
blåshalsen ▼



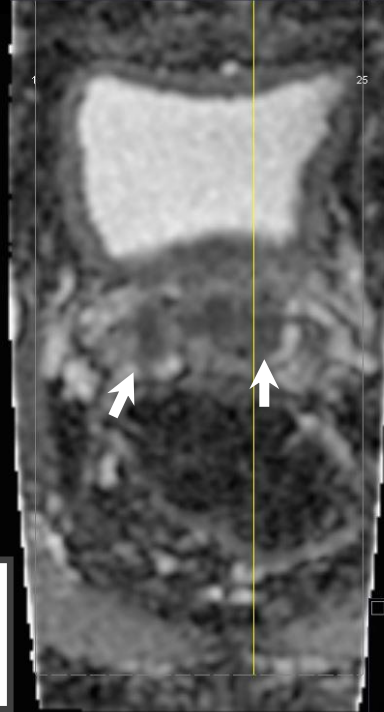
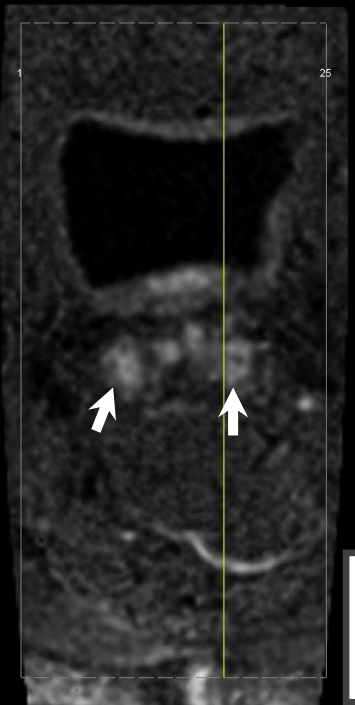
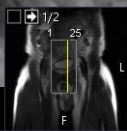
SVI 5



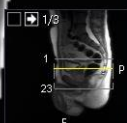Fall 3



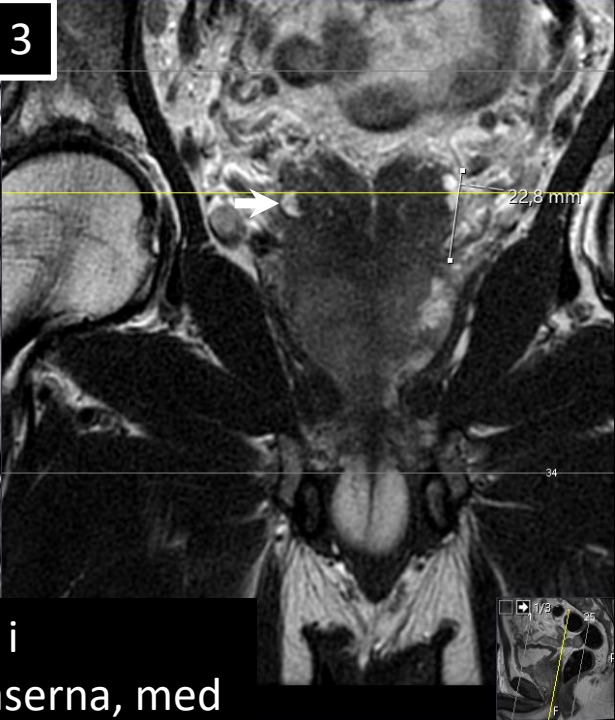
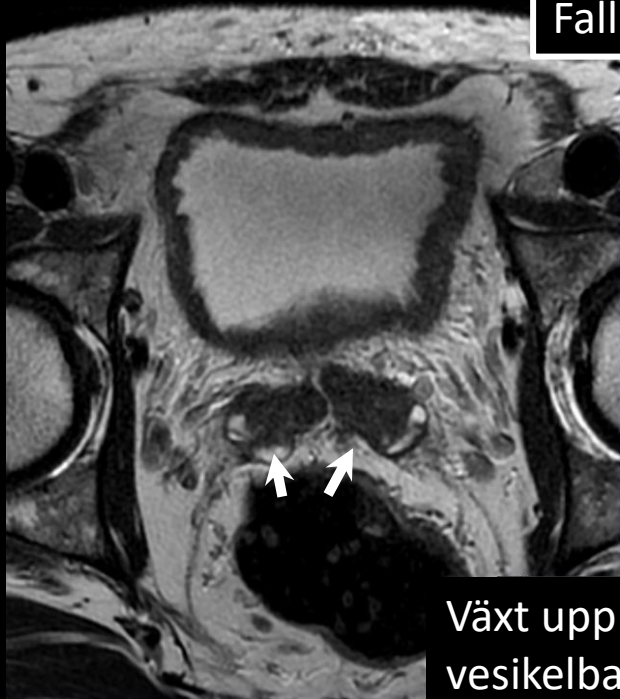Växt upp i vesikelbaserna



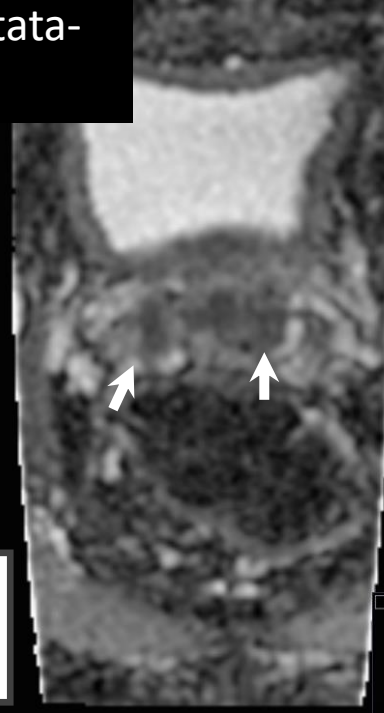
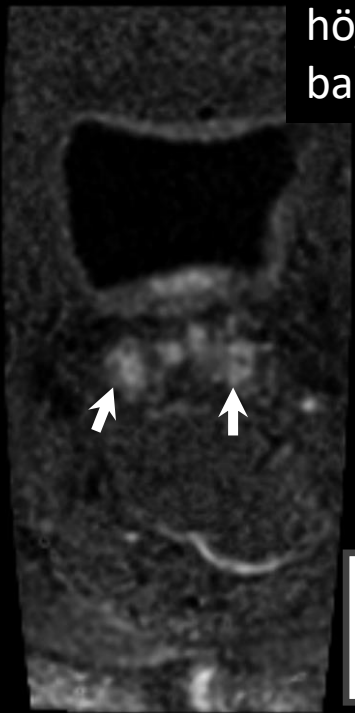
SVI 5



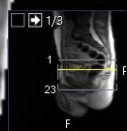
Fall 3



Växt upp i vesikelbaserna, med höjd ovan prostata-basen



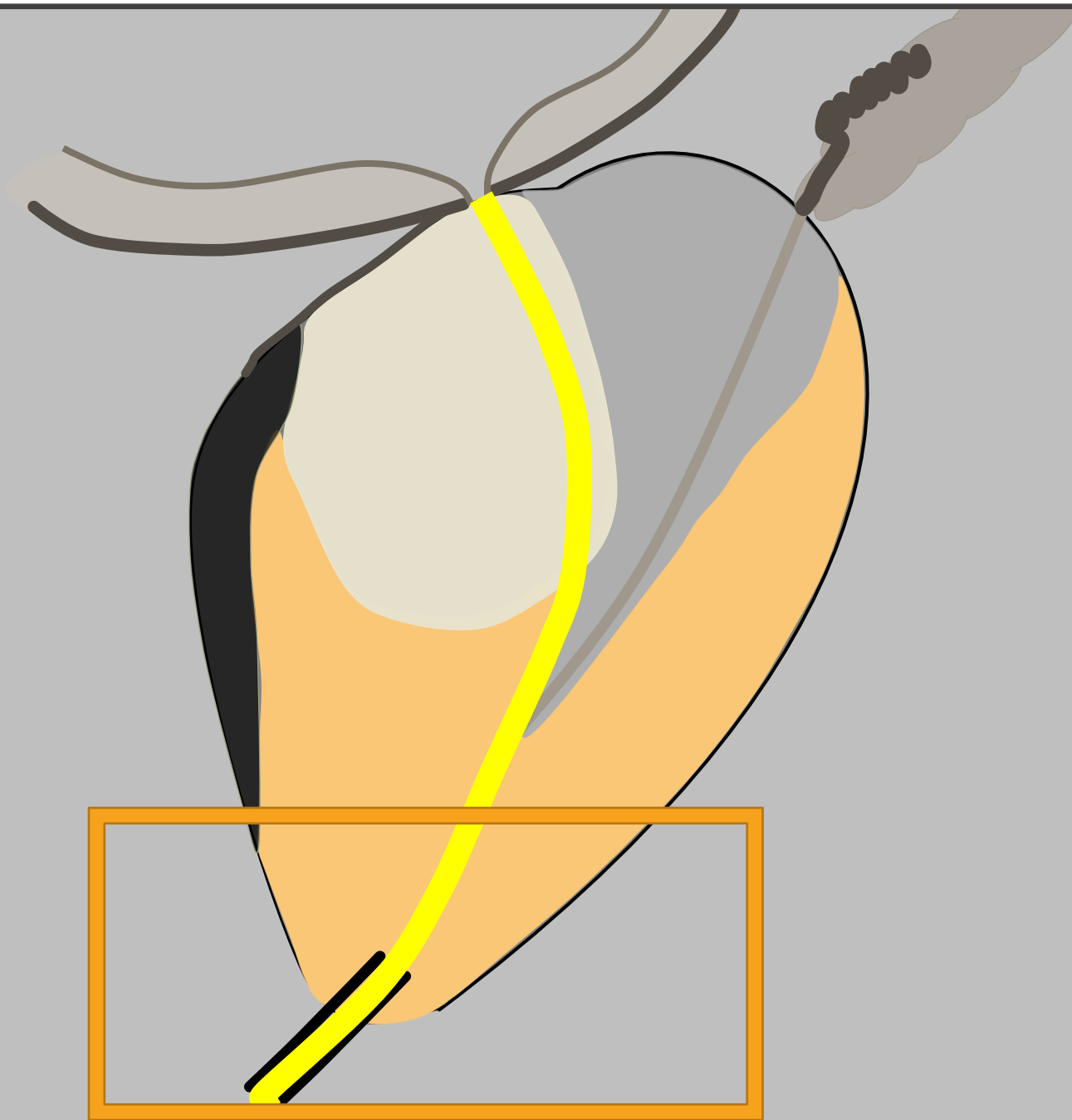
SVI 5



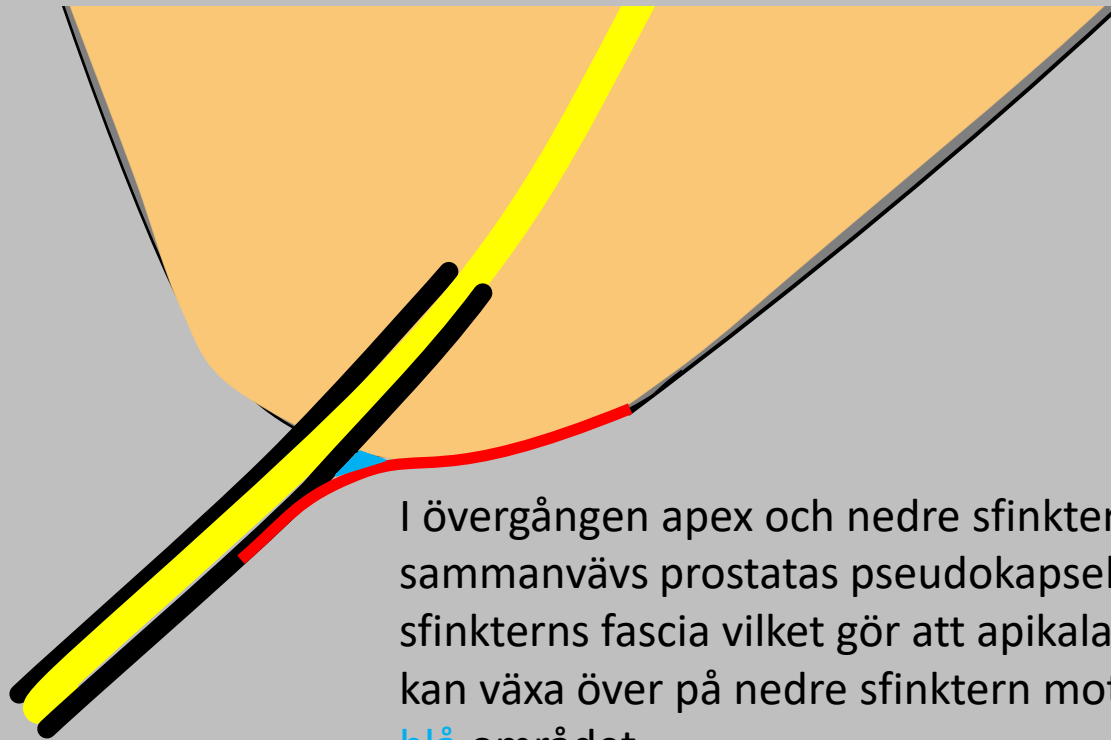
STADIEINDELNING

- LOKAL STADIEINDELNING
 - Extraprostatisk extension (EPE)
 - Seminalvesikel-invasion (SVI)
 - **Nedre sfinkter (NS)**
 - *Blåshals*

BLÅSHALS OCH NEDRE SFINKTER



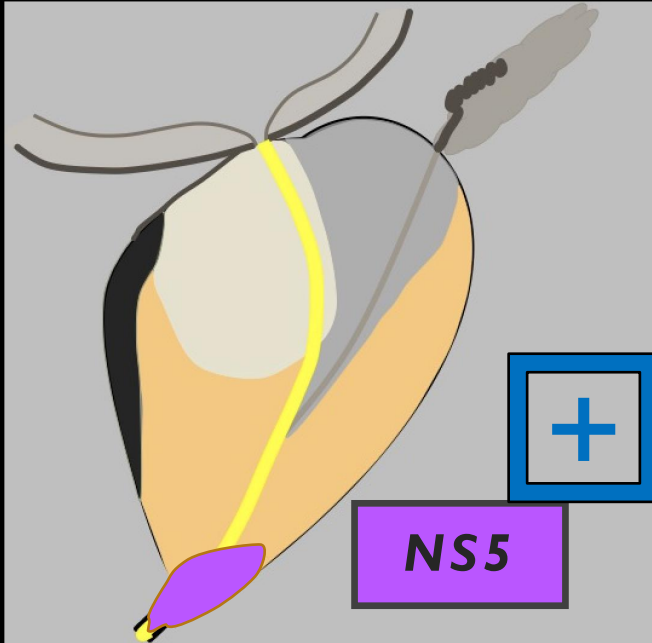
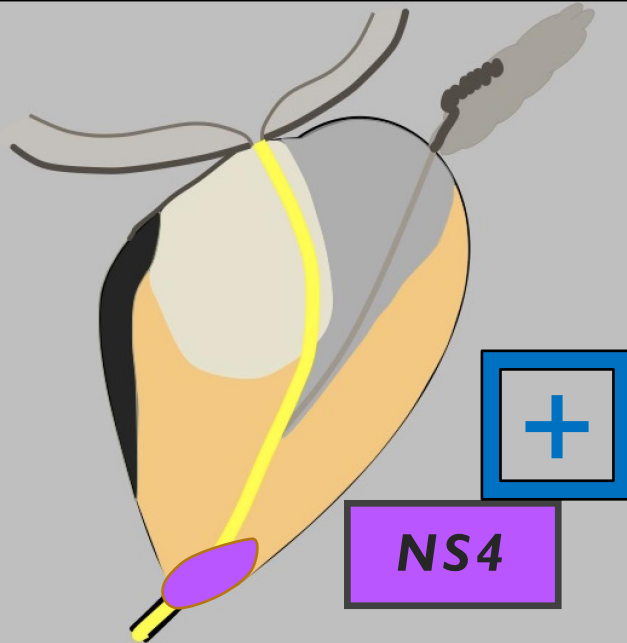
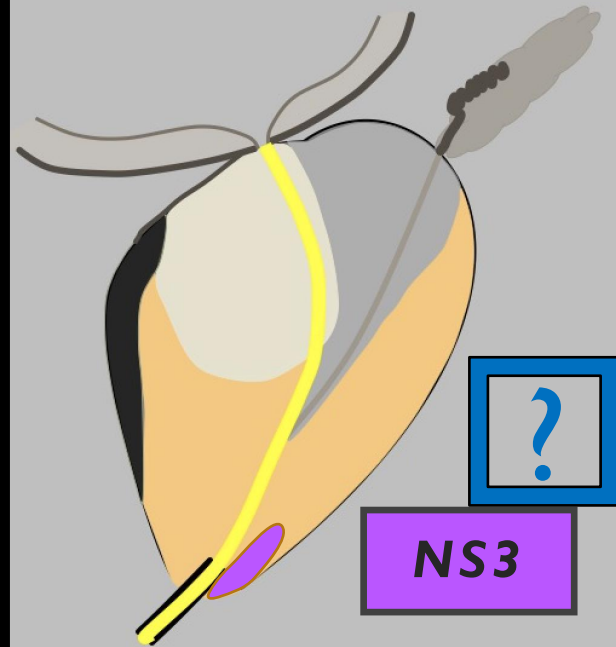
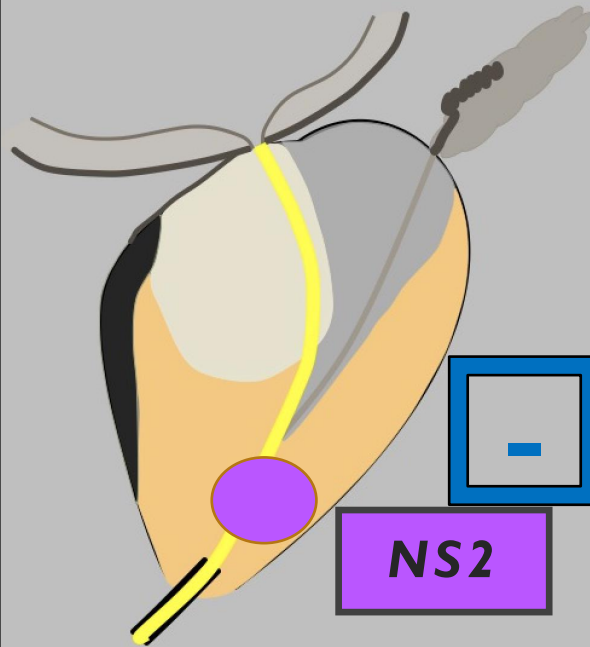
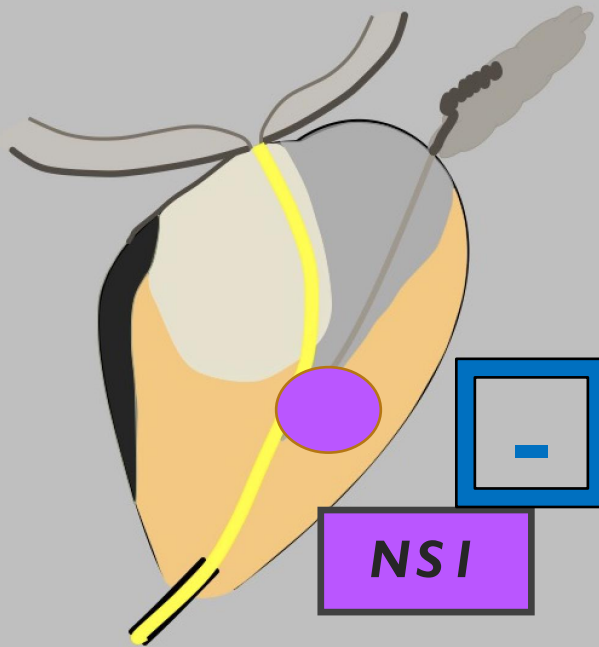
NEDRE SFINKTER OCH KAPSELN



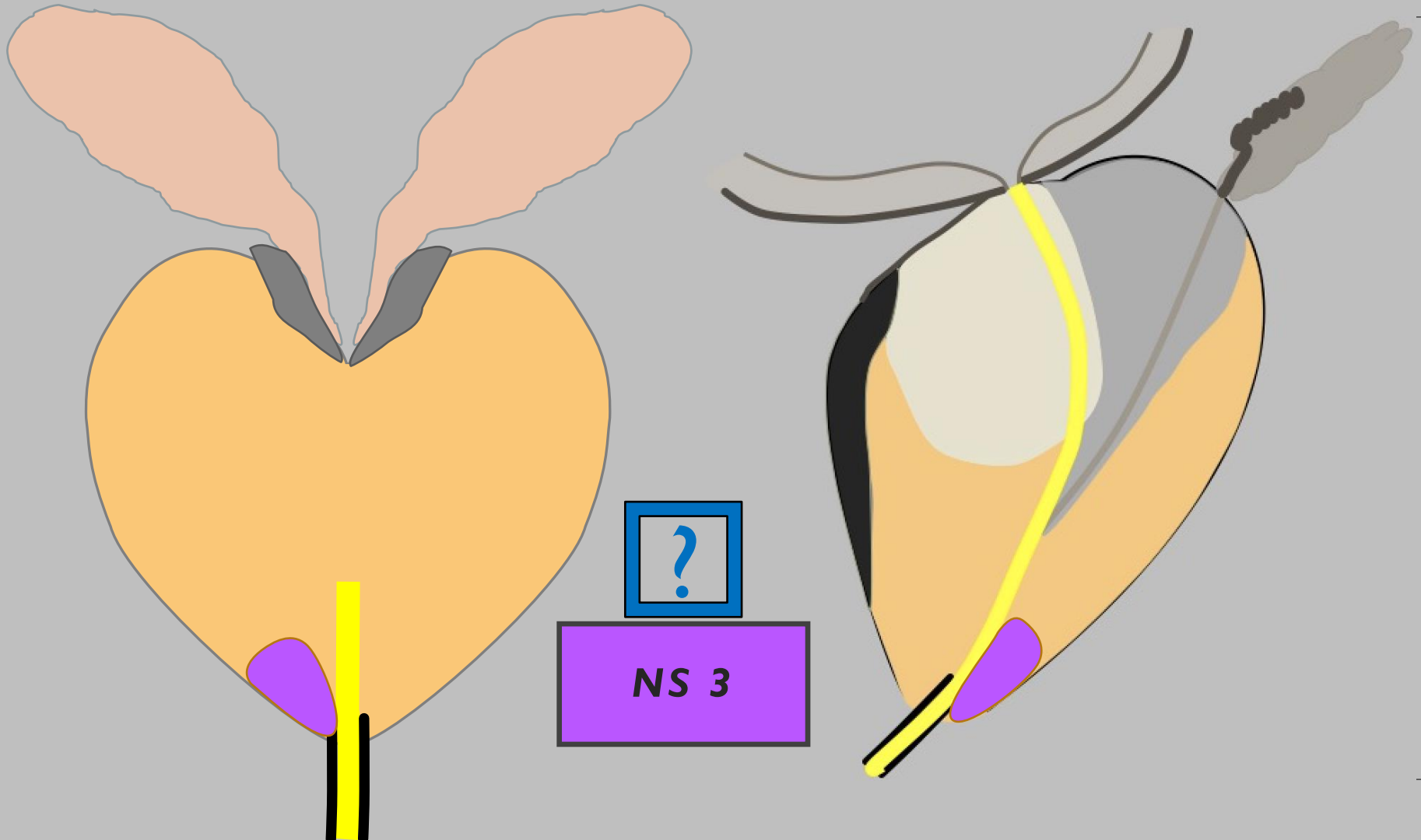
I övergången apex och nedre sfinktermuskulaturen sammanvävs prostatas pseudokapseln med nedre sfinkterns fascia vilket gör att apikala tumörer lättare kan växa över på nedre sfinktern motsvarande det blå området.

Beskrivning av tumörens växt i förhållande till apex är viktig information för kirurgen för att kunna undvika positiva kirurgiska marginaler.

NEDRE SFINKTER (NS)



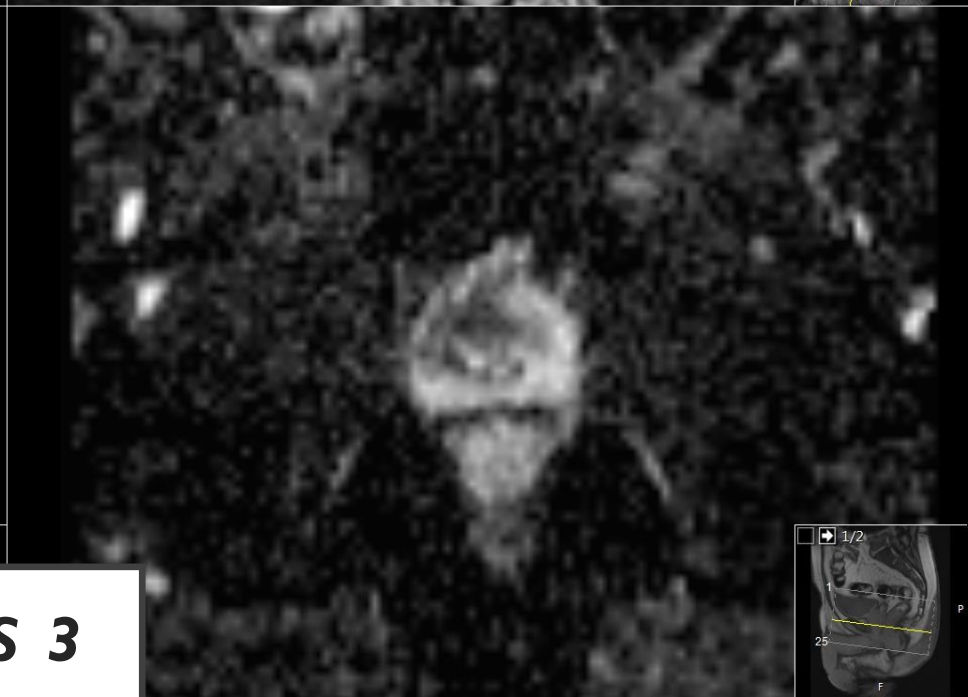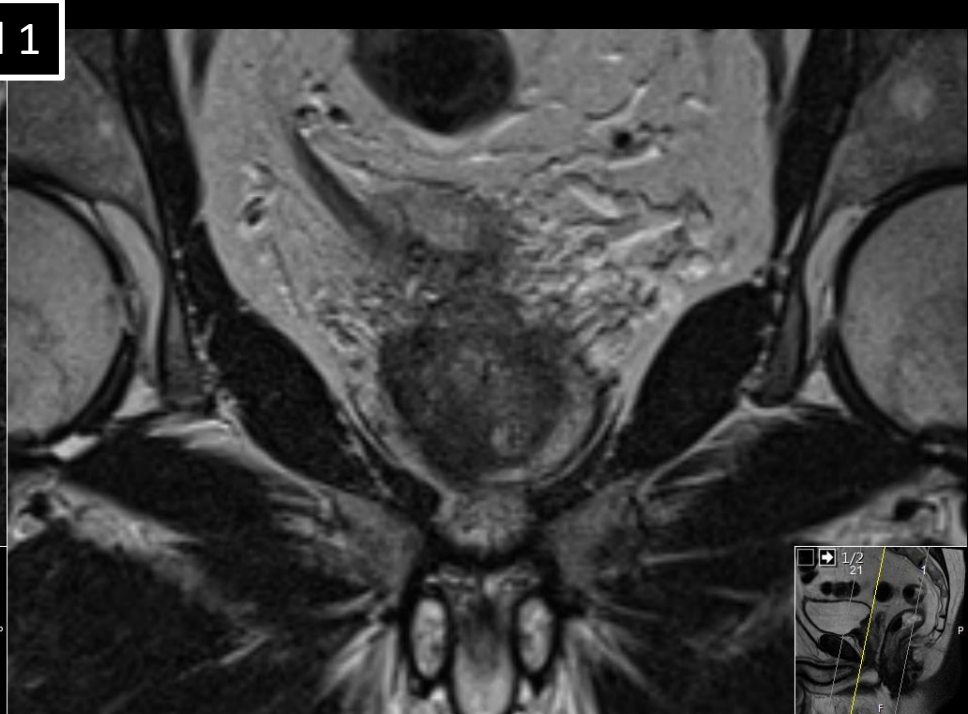
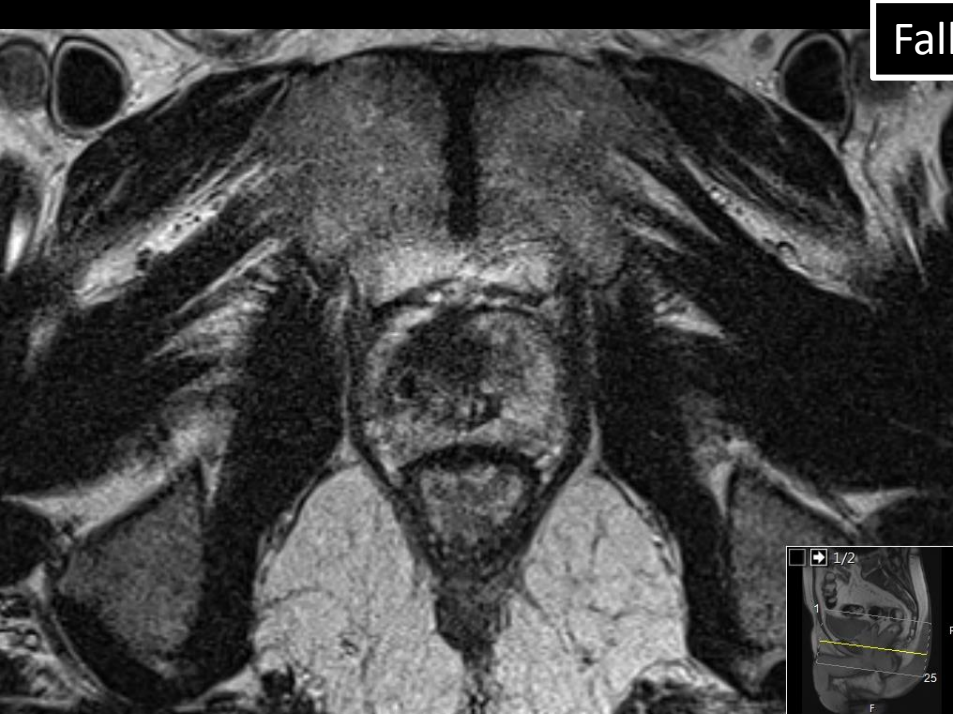NEDRE SFINKTER (NS)



?

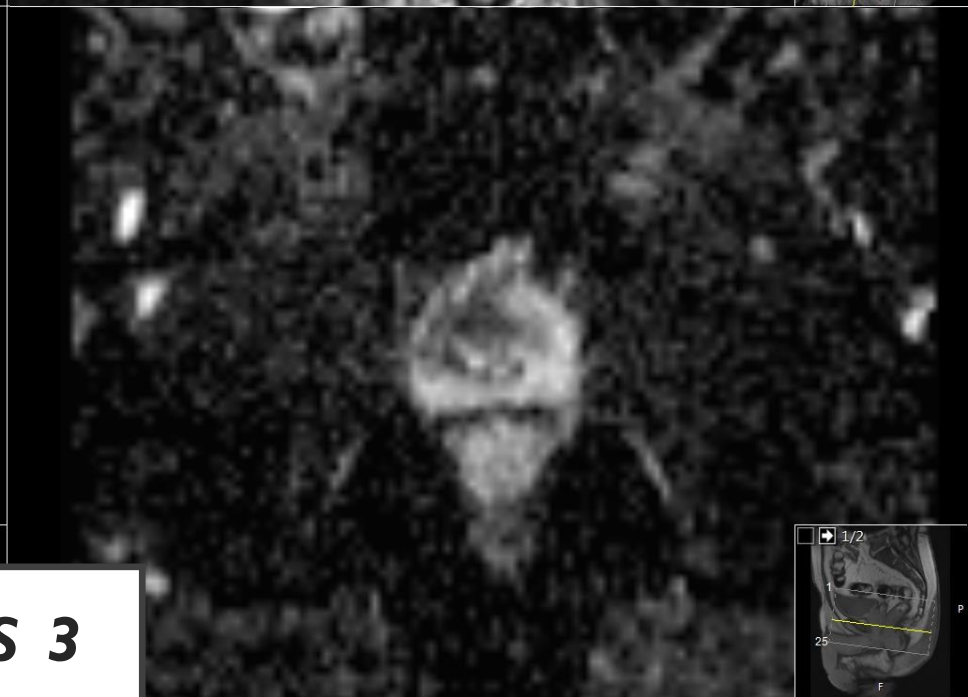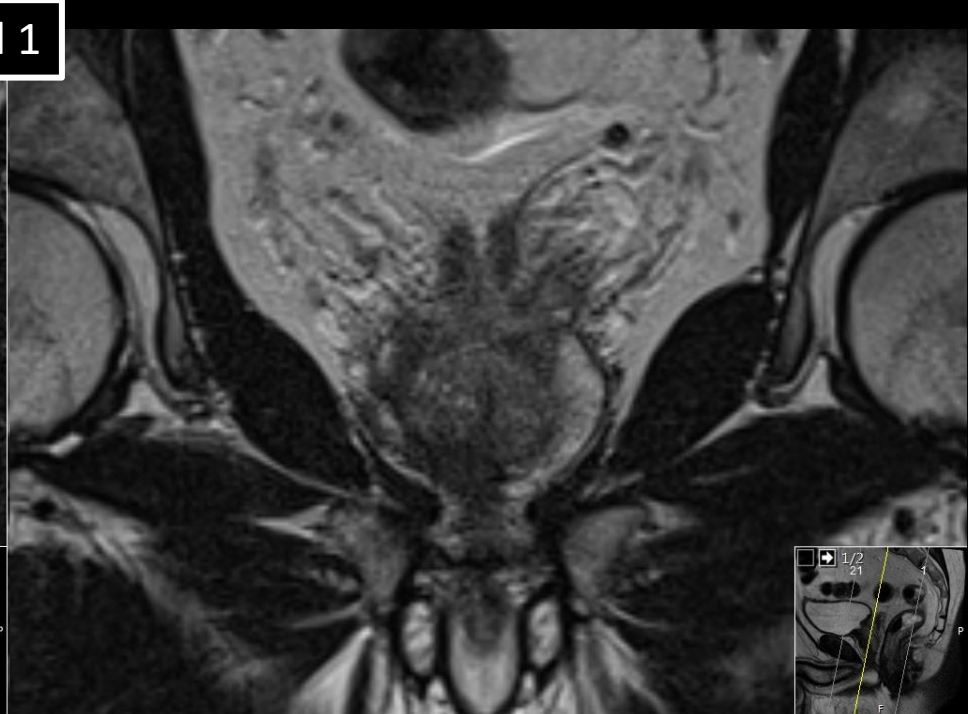
NS 3

Fall 1



NS 3

Fall 1



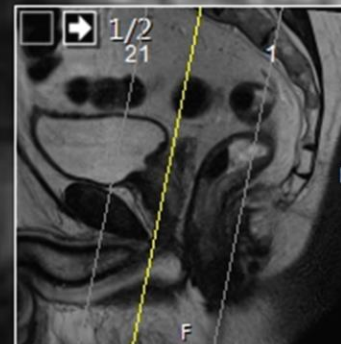NS 3

Fall 1

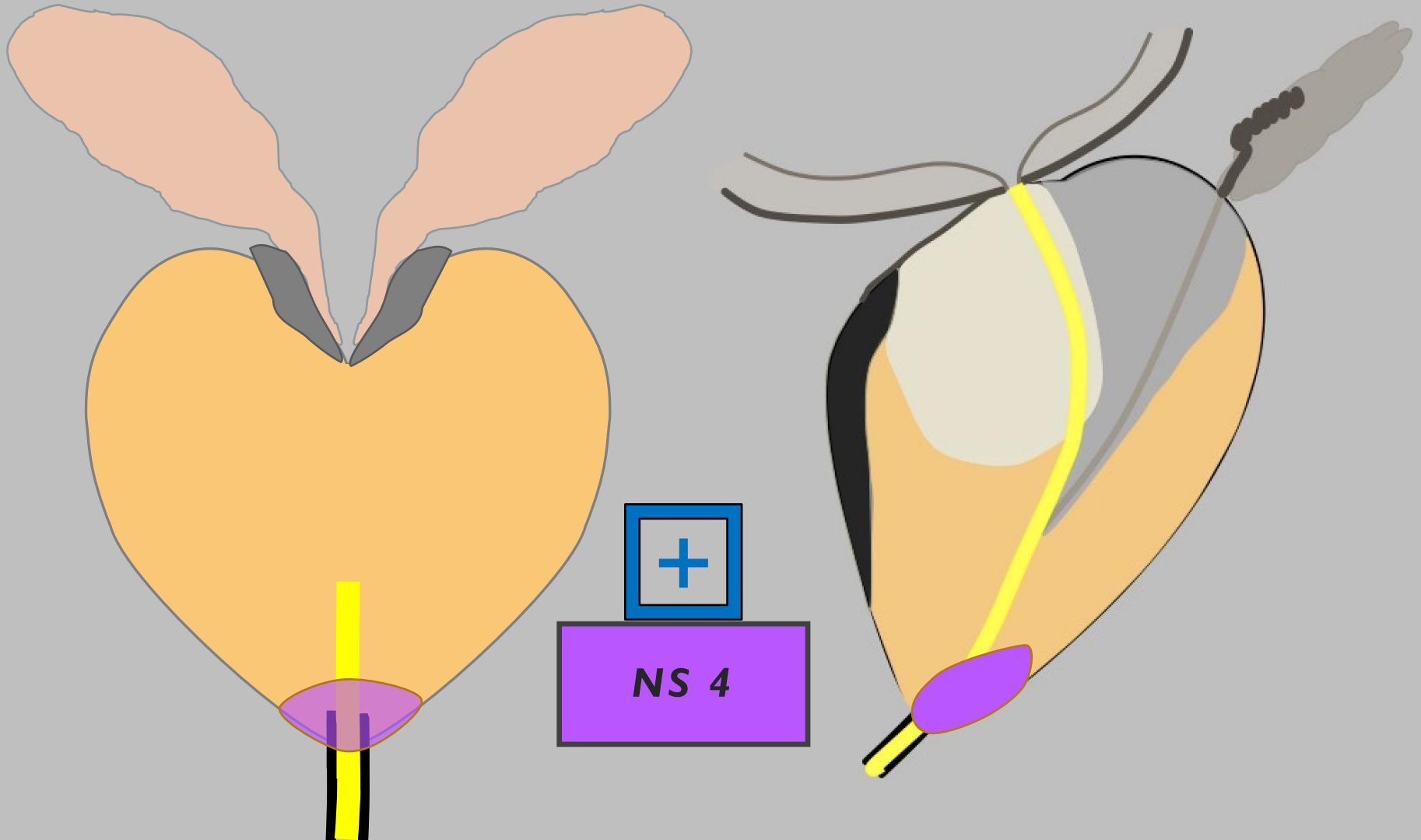
Tumör i apex utan att säkert
växa över på nedre sfinktern



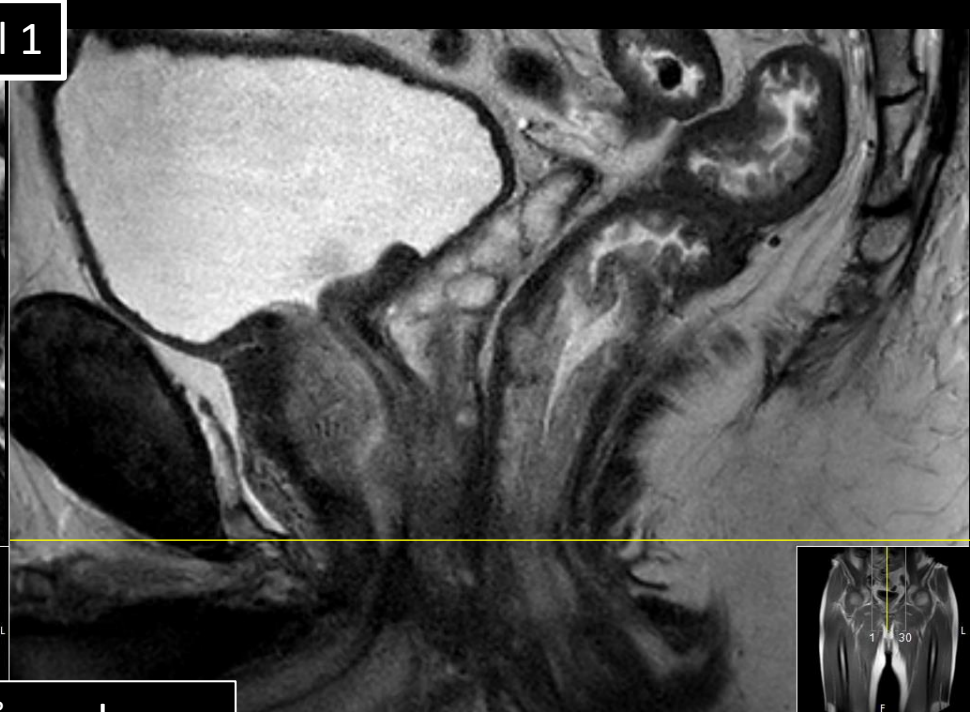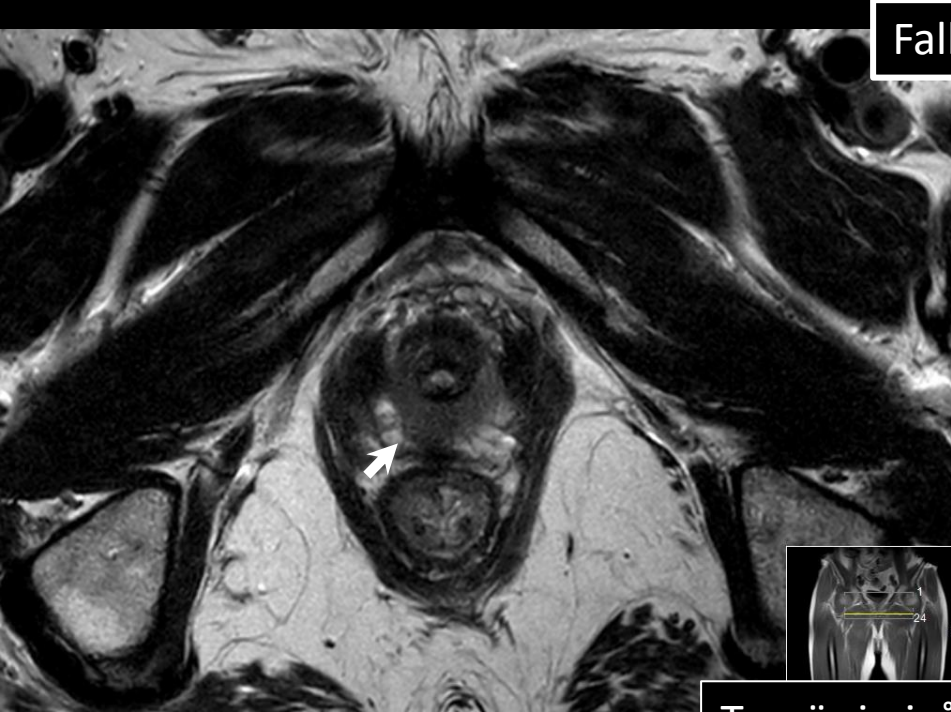NS 3



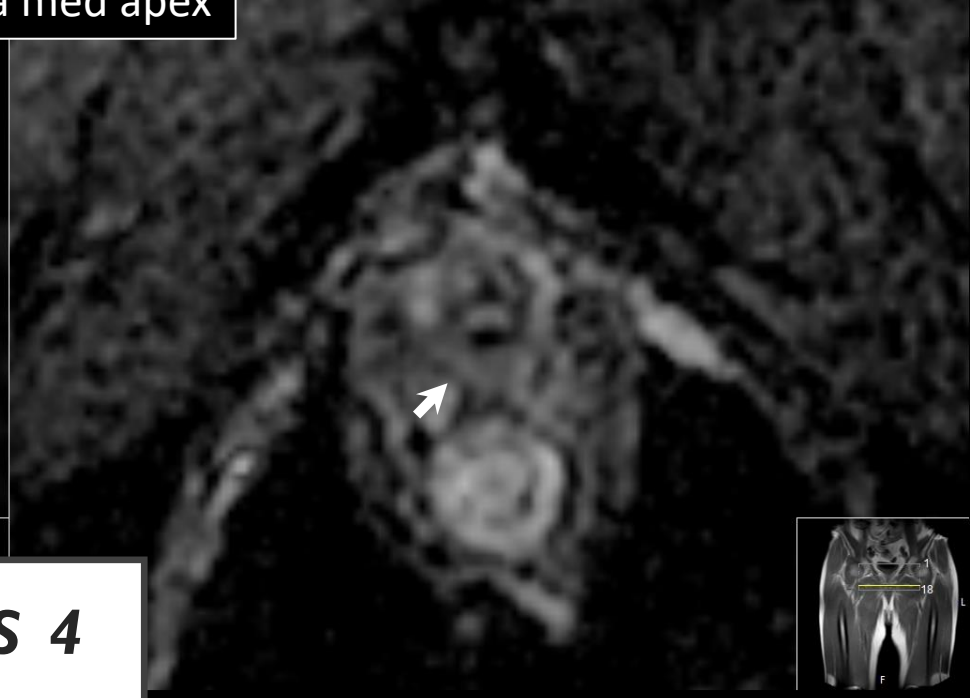
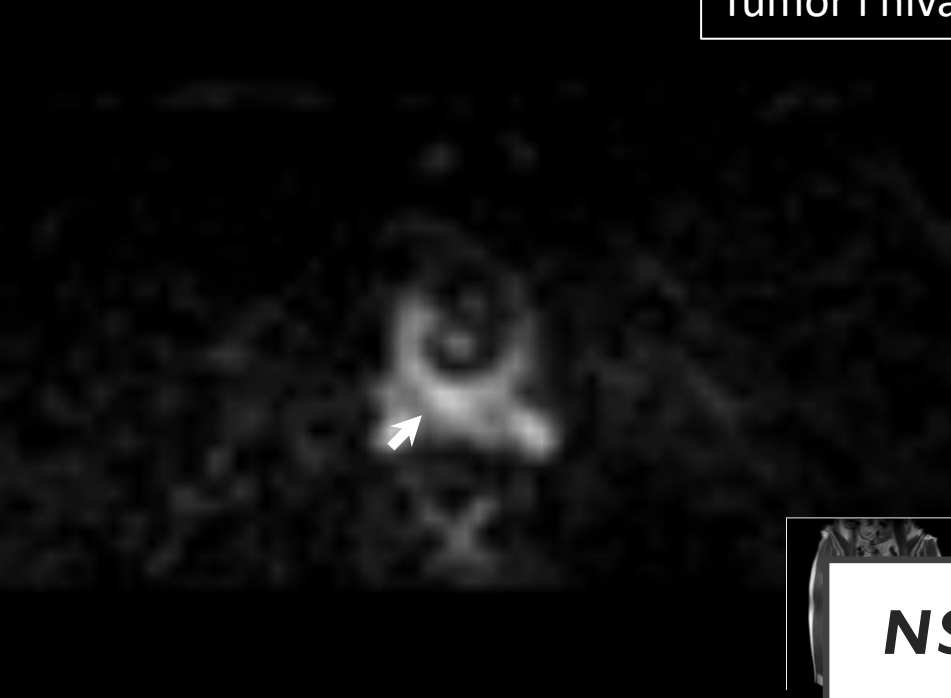NEDRE SFINKTER (NS)



Fall 1

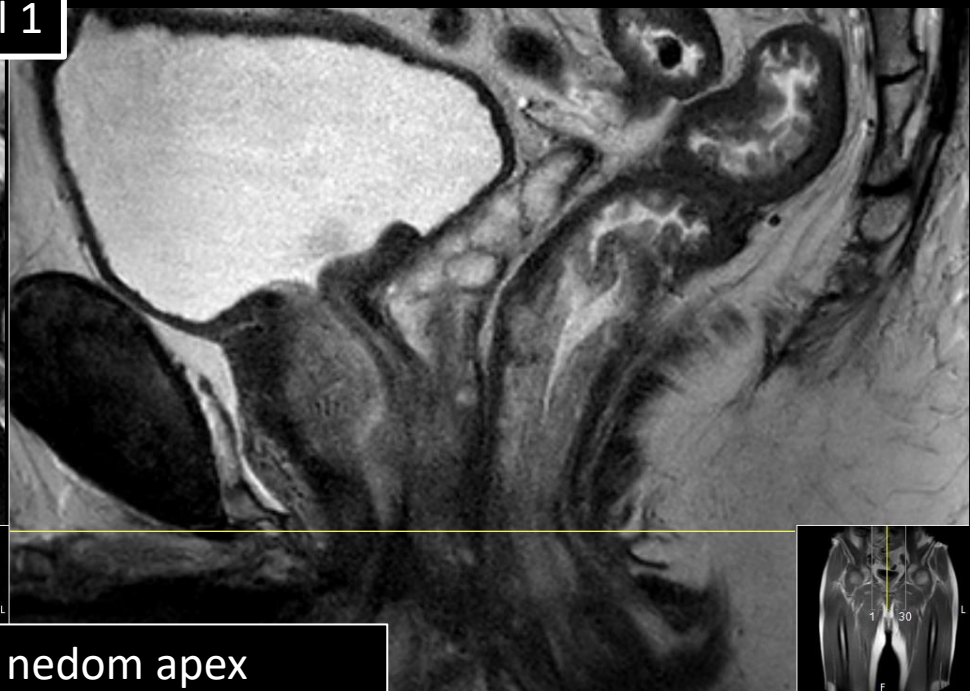
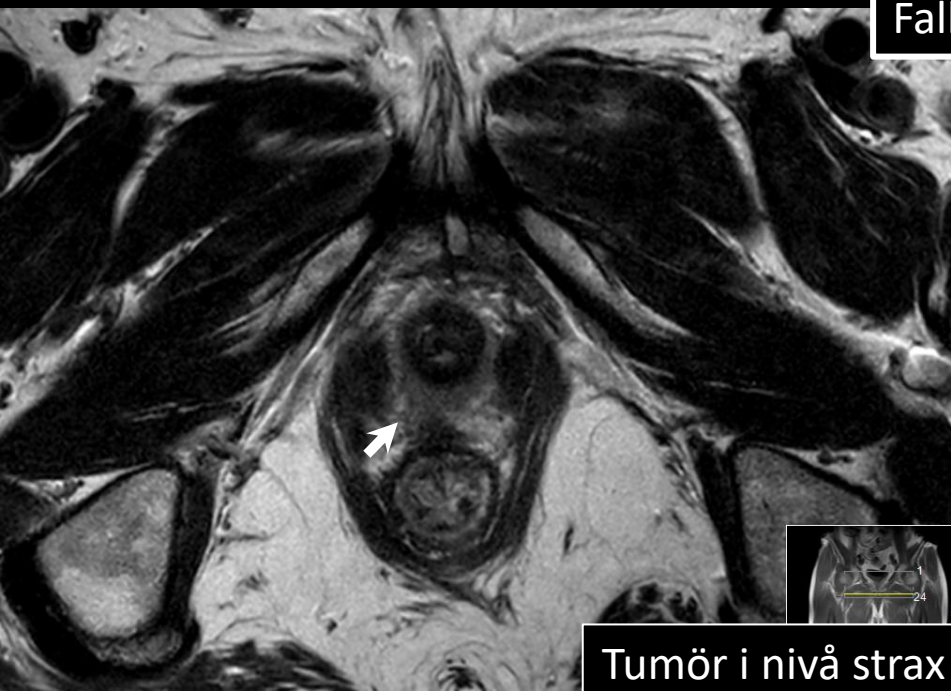


Tumör i nivå med apex

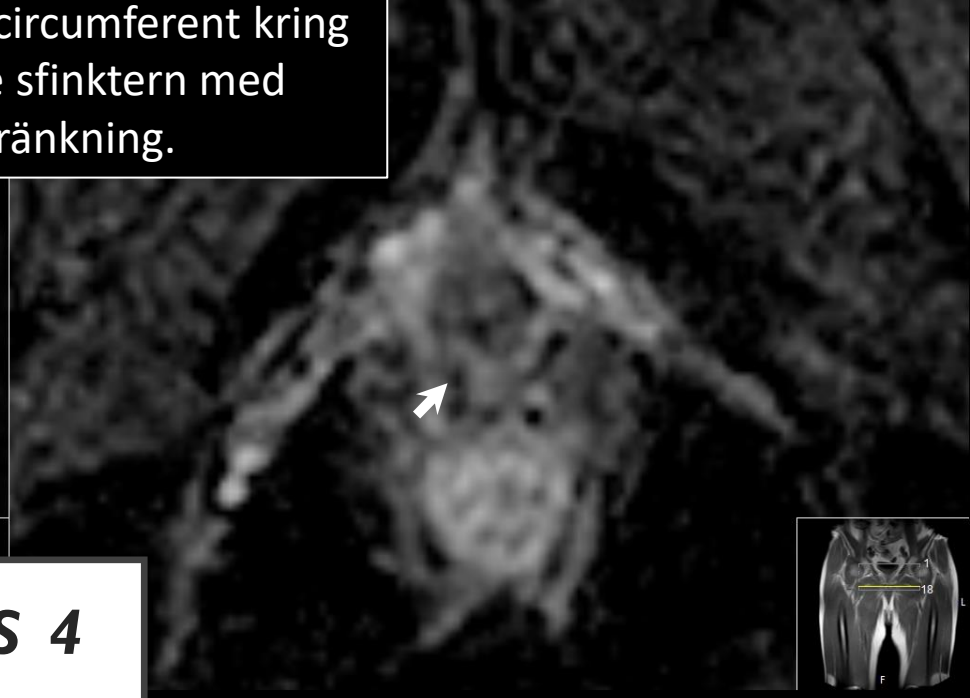
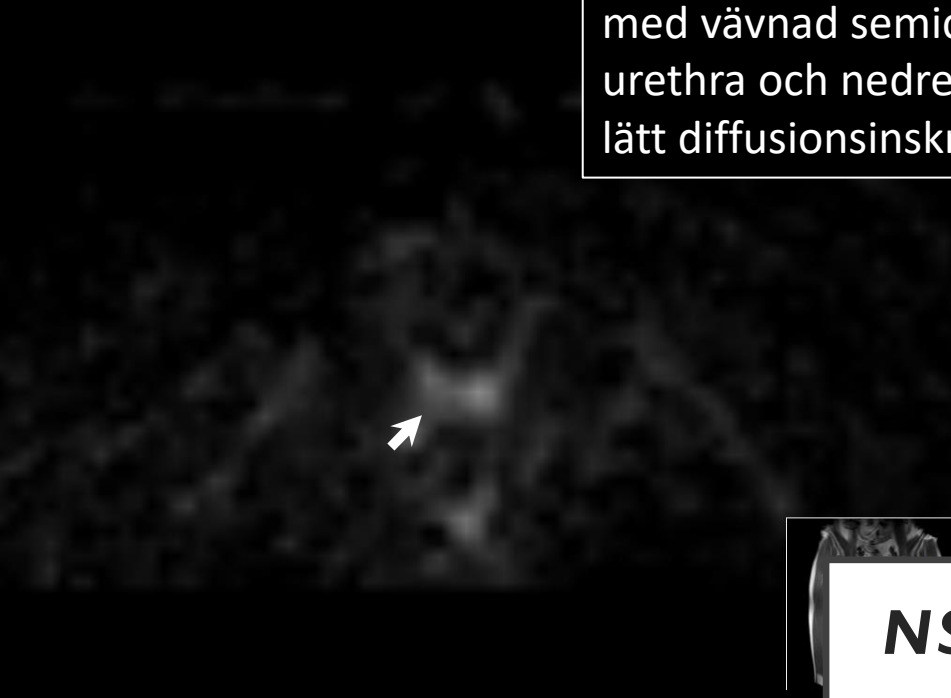

NS 4

Fall 1

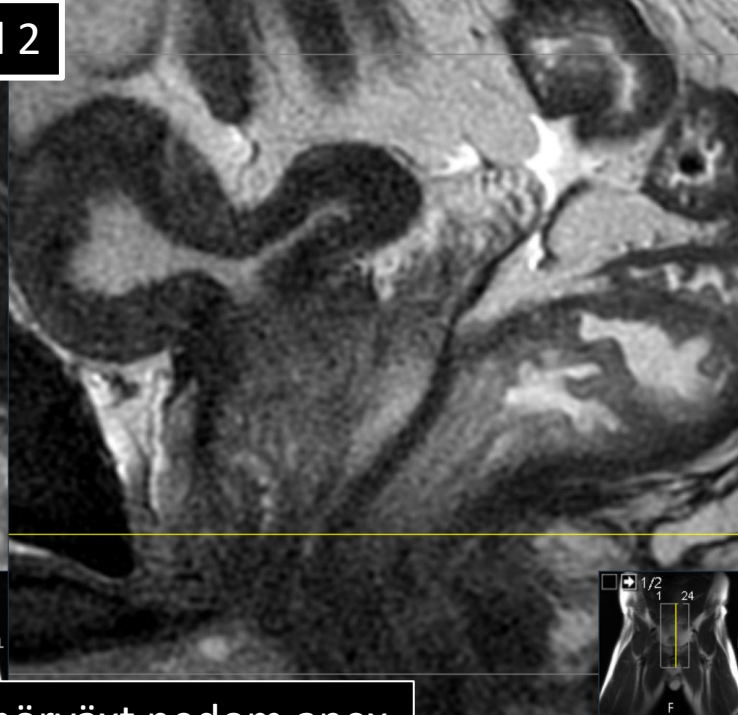
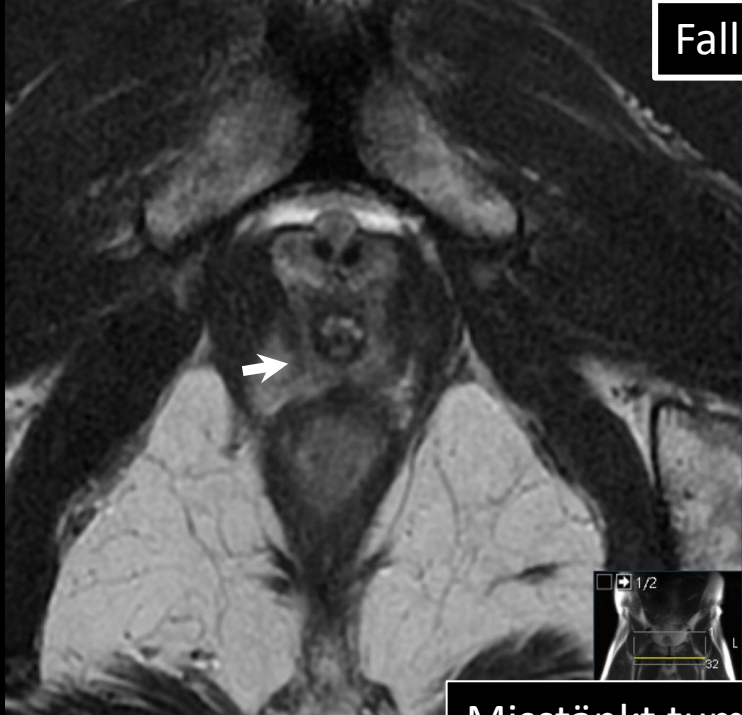

Tumör i nivå strax nedom apex med vävnad semicircumferent kring urethra och nedre sfinktern med lätt diffusionsinskränkning.

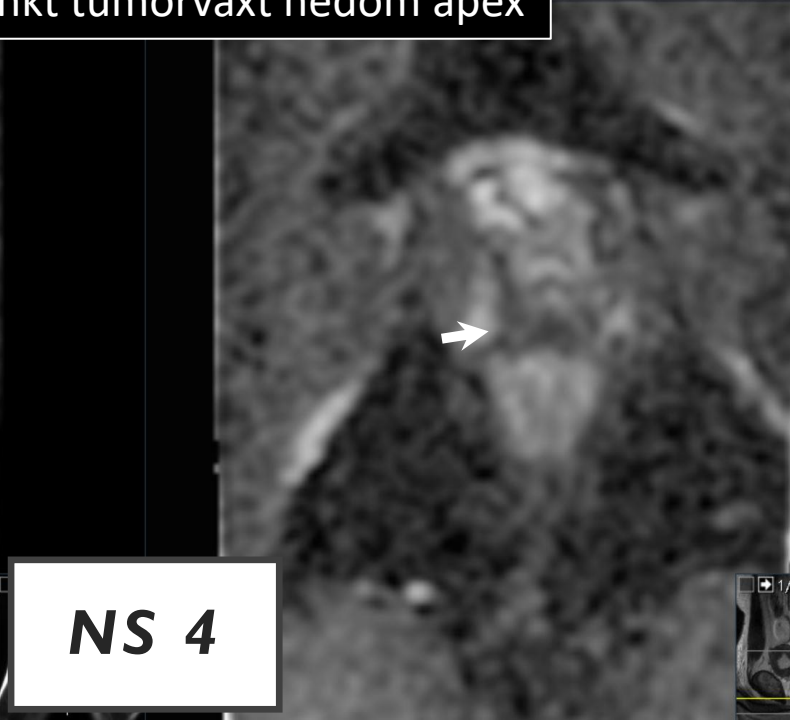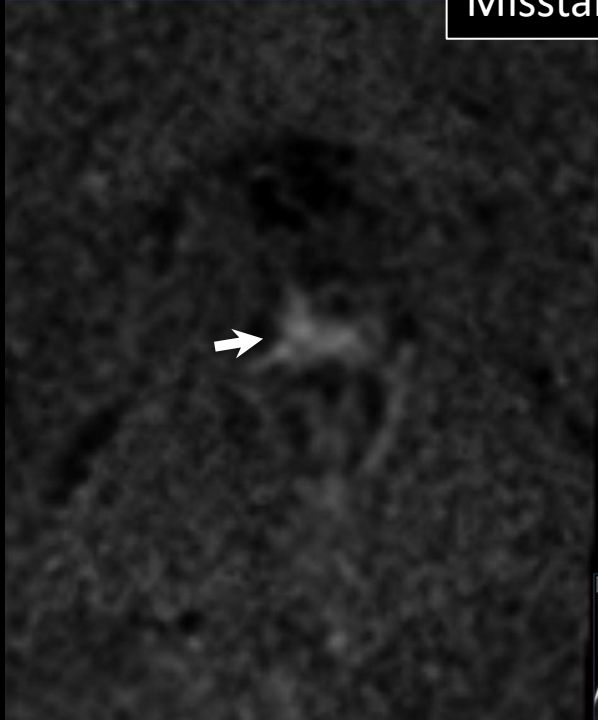


NS 4

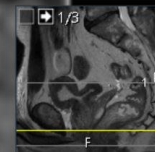
Fall 2



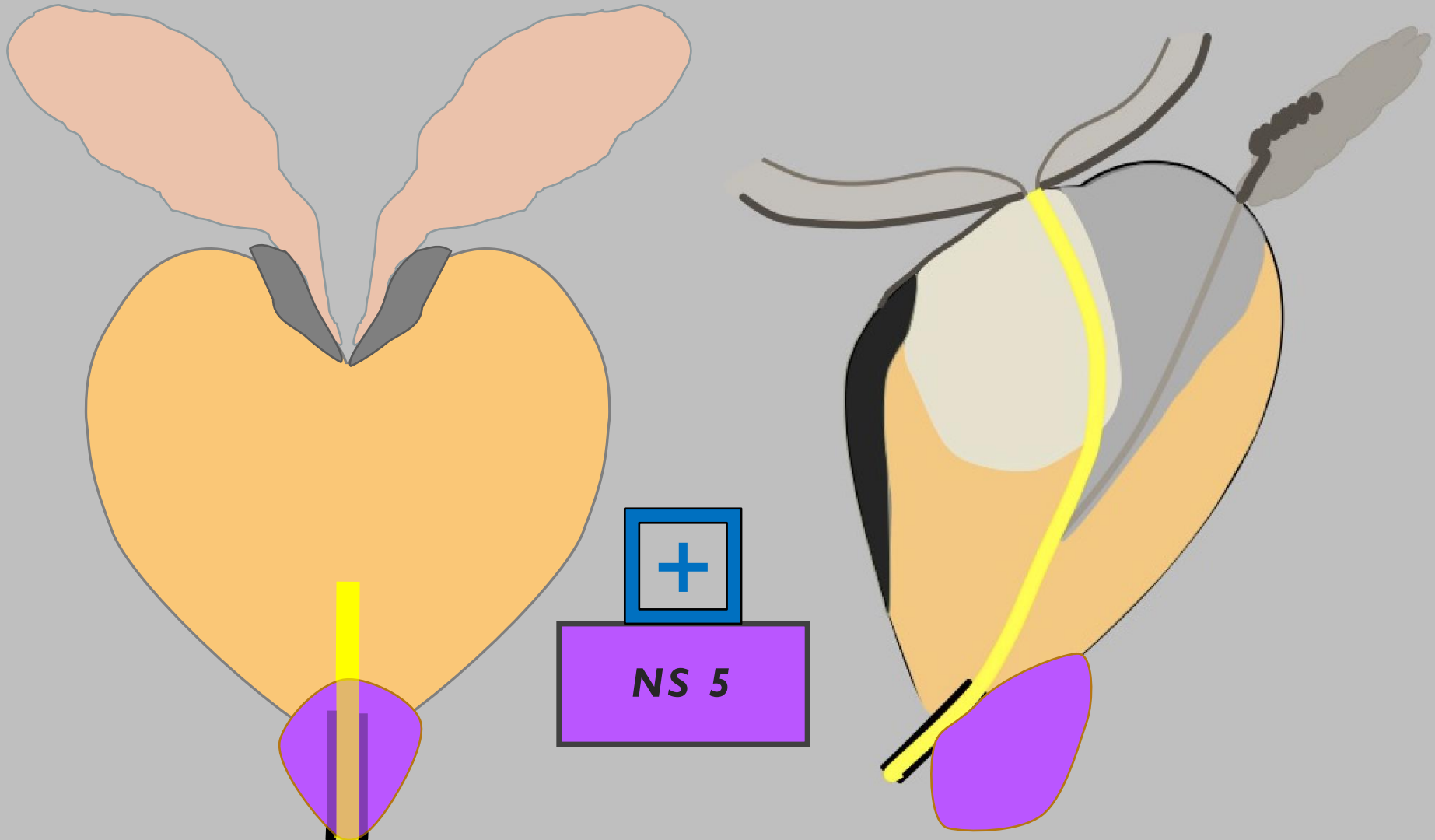
Misstänkt tumörväxt nedom apex

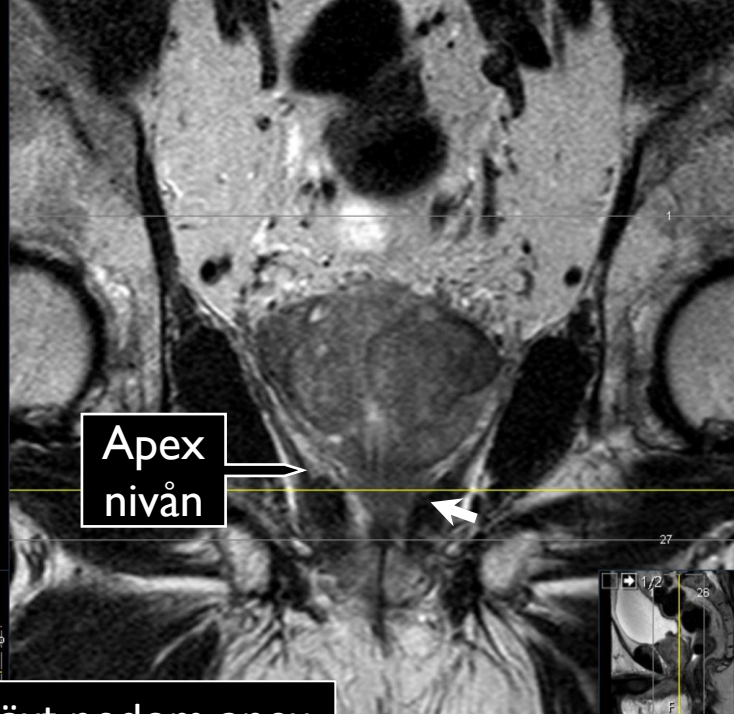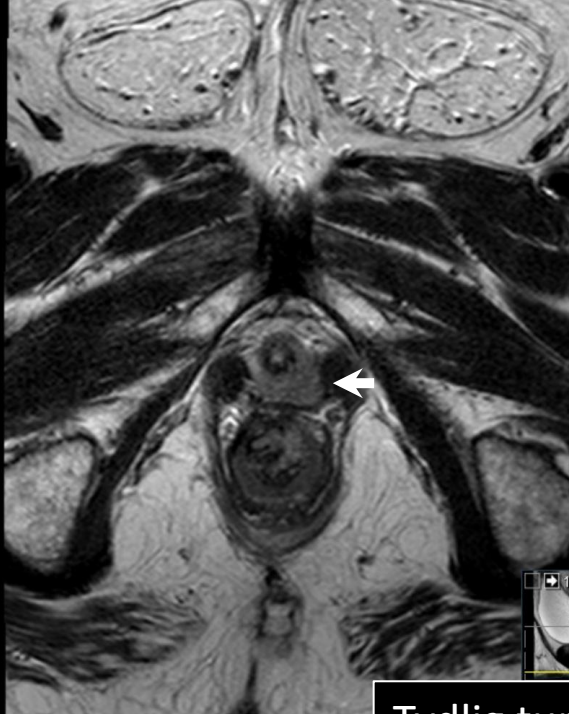


NS 4

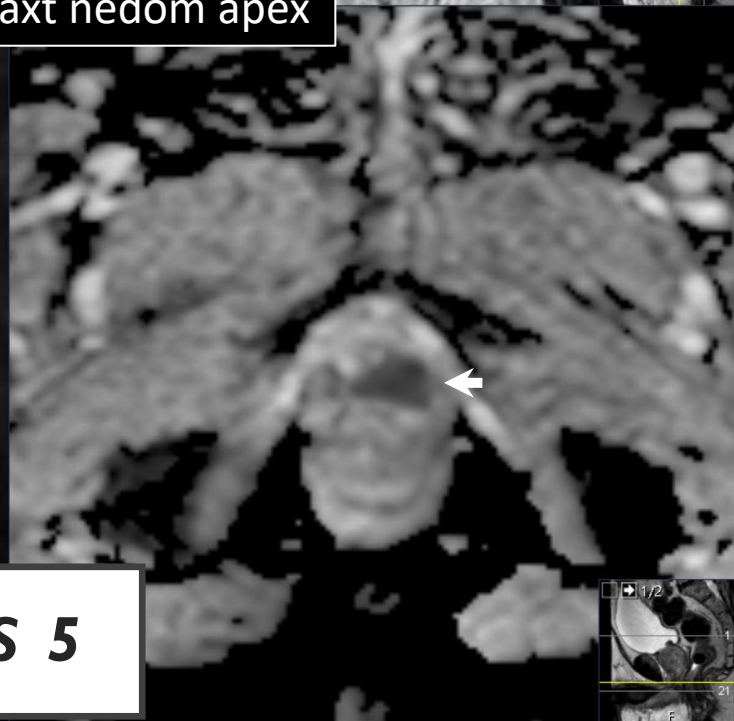
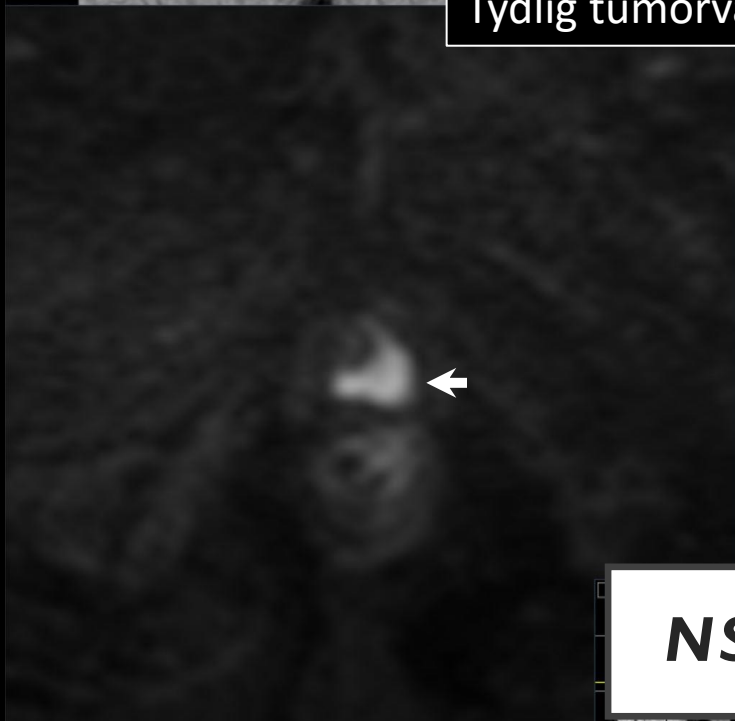

NEDRE SFINKTER (NS)





Tydlig tumörväxt nedom apex



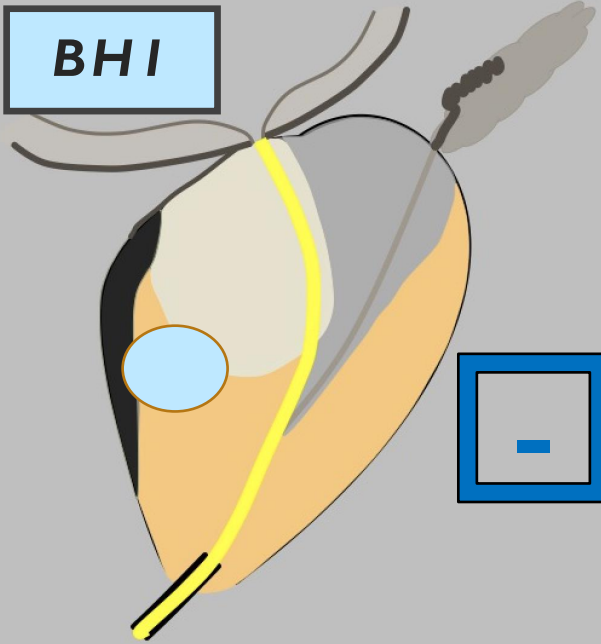
NS 5

STADIEINDELNING

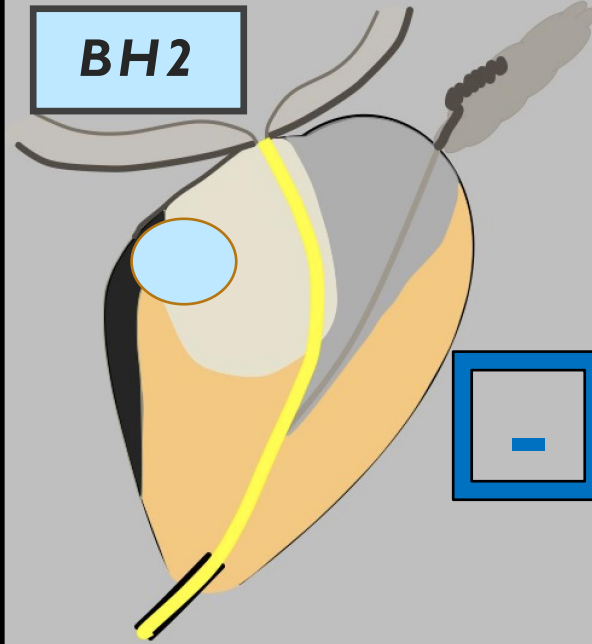
- LOKAL STADIEINDELNING
 - Extraprostatisk extension (EPE)
 - Seminalvesikel-invasion (SVI)
 - *Nedre sfinkter (NS)*
 - ***Blåshals (BH)***

BLÅSHALS (BH)

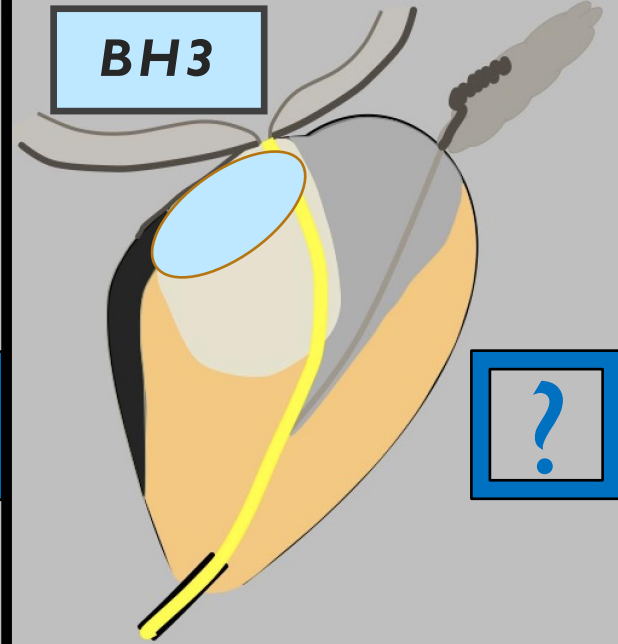
BH1



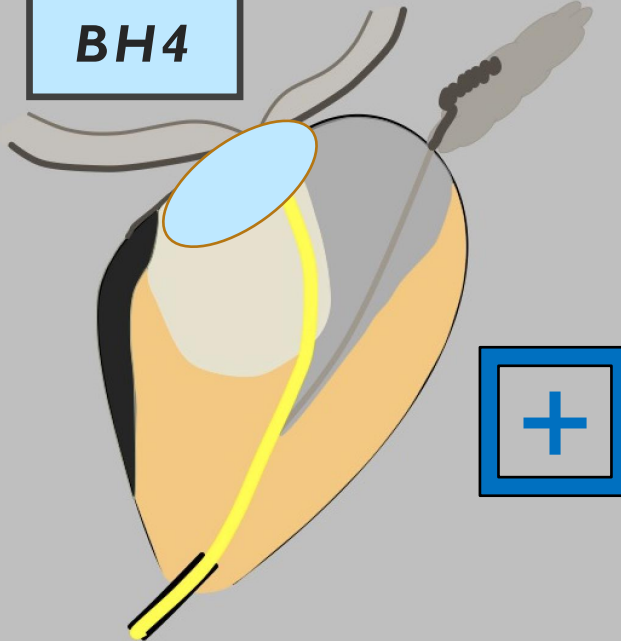
BH2



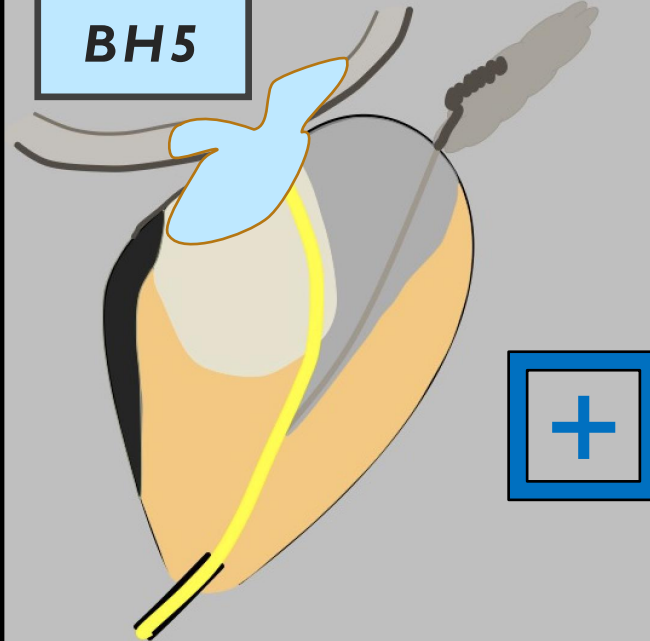
BH3



BH4



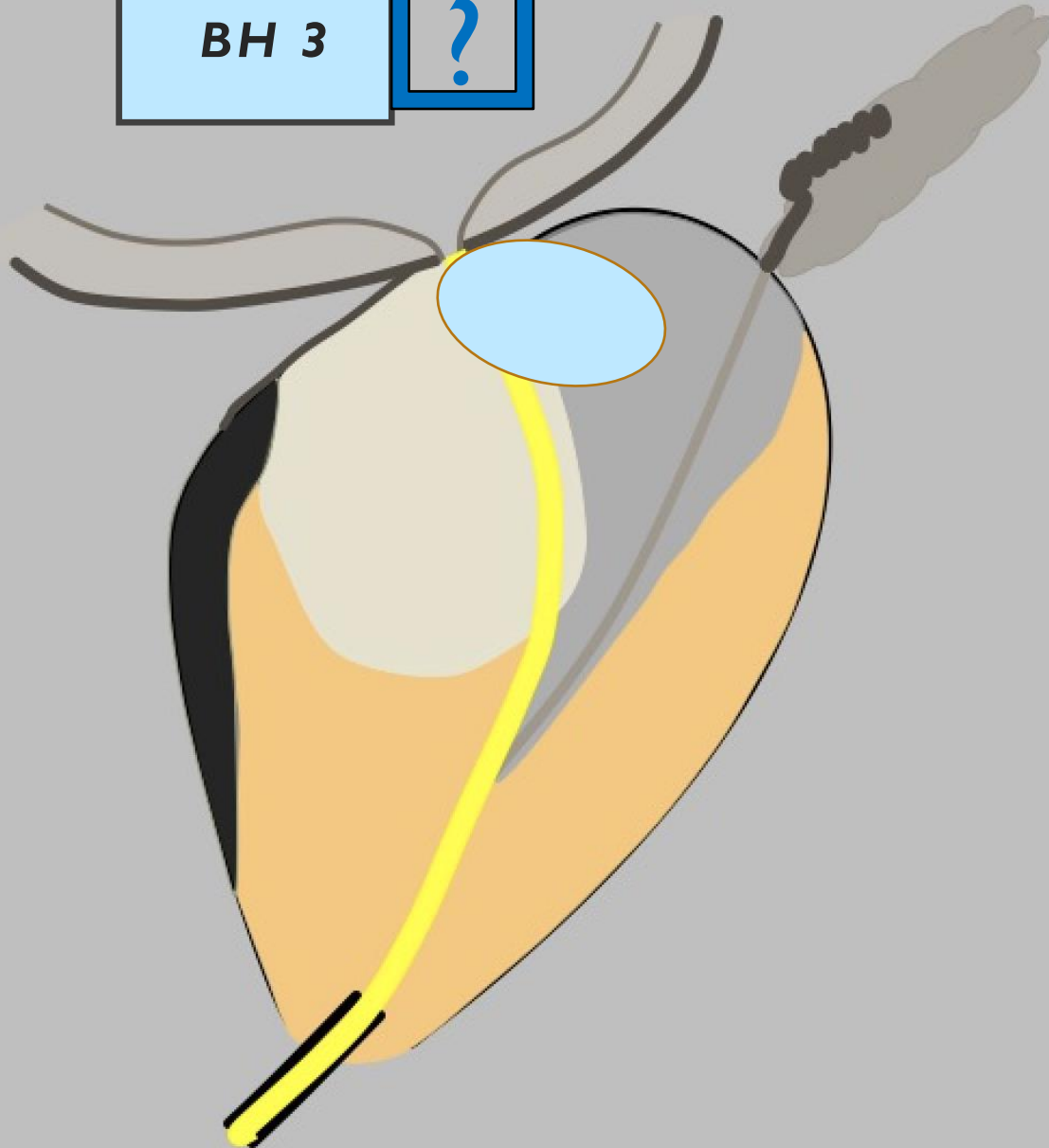
BH5



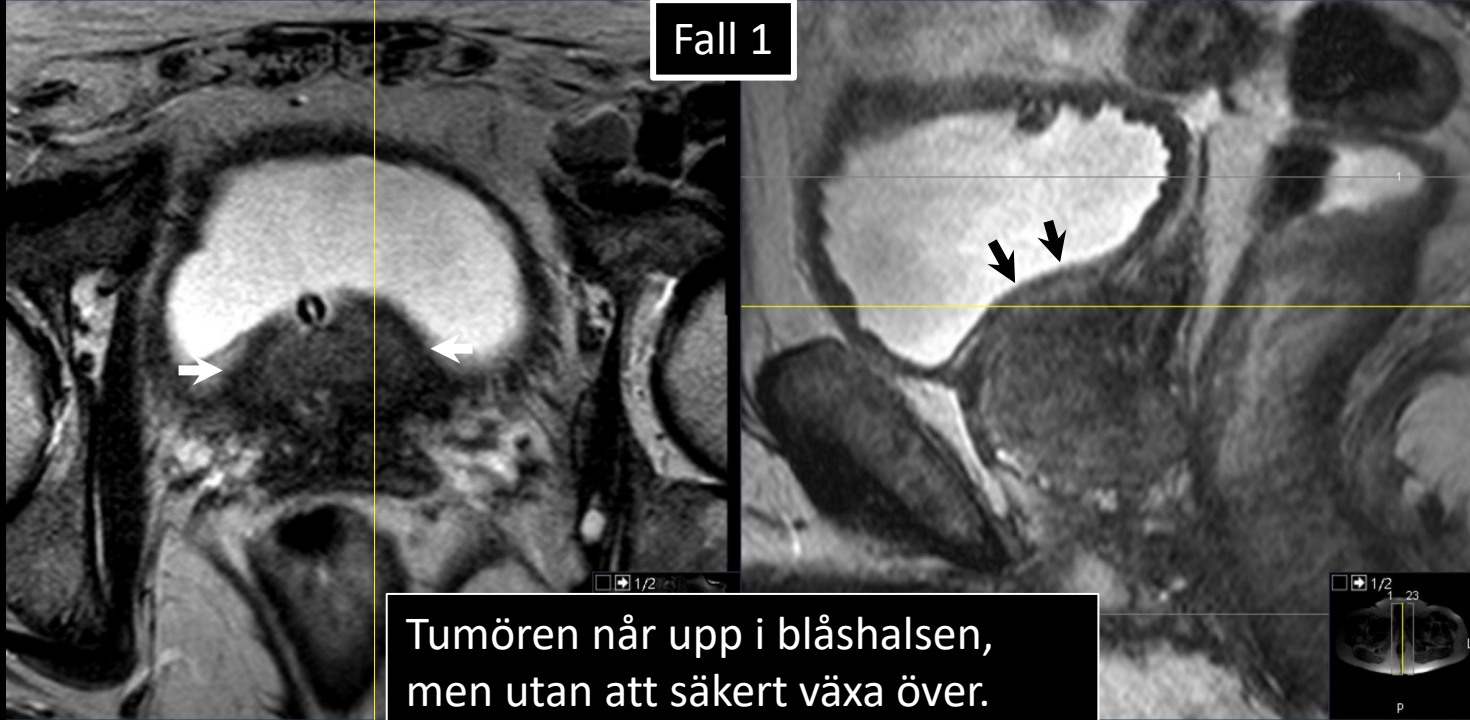
BLÅSHALS (BH)

BH 3

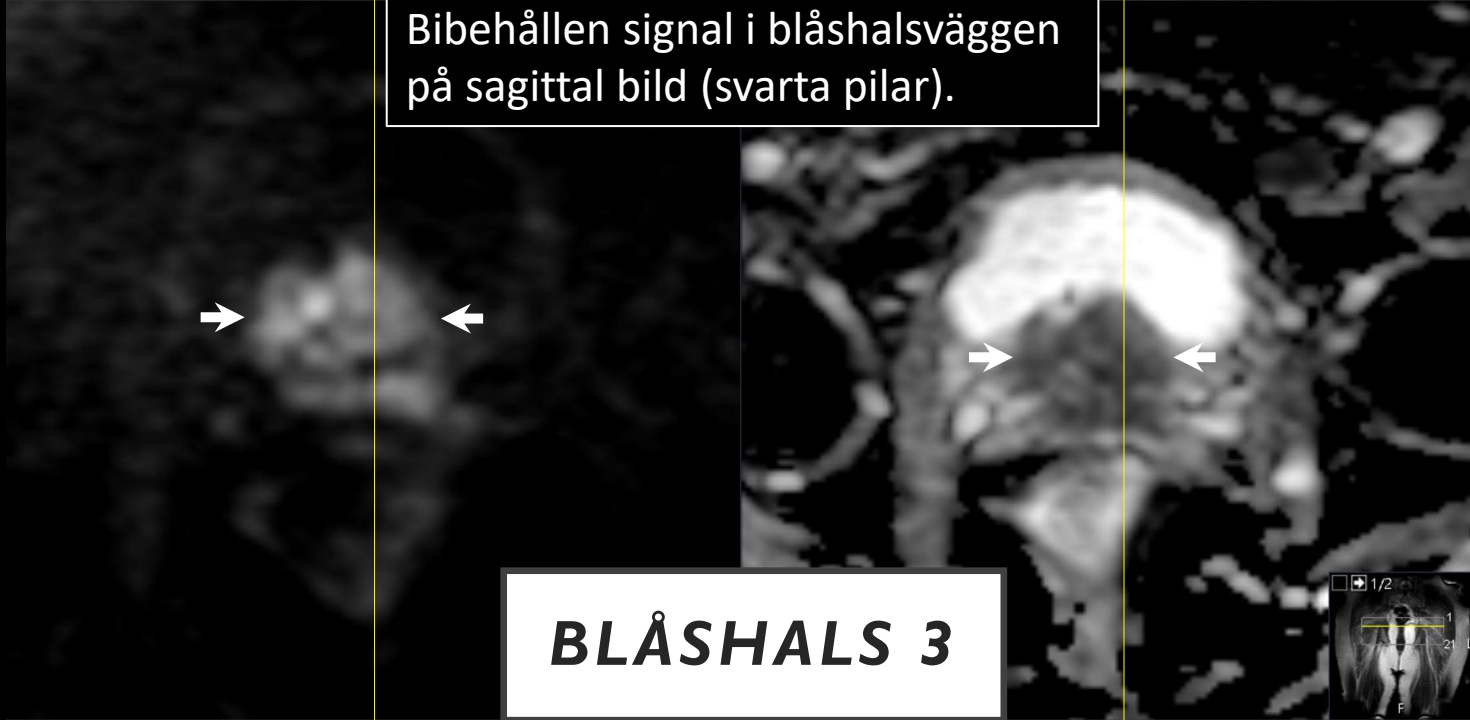
?



Fall 1

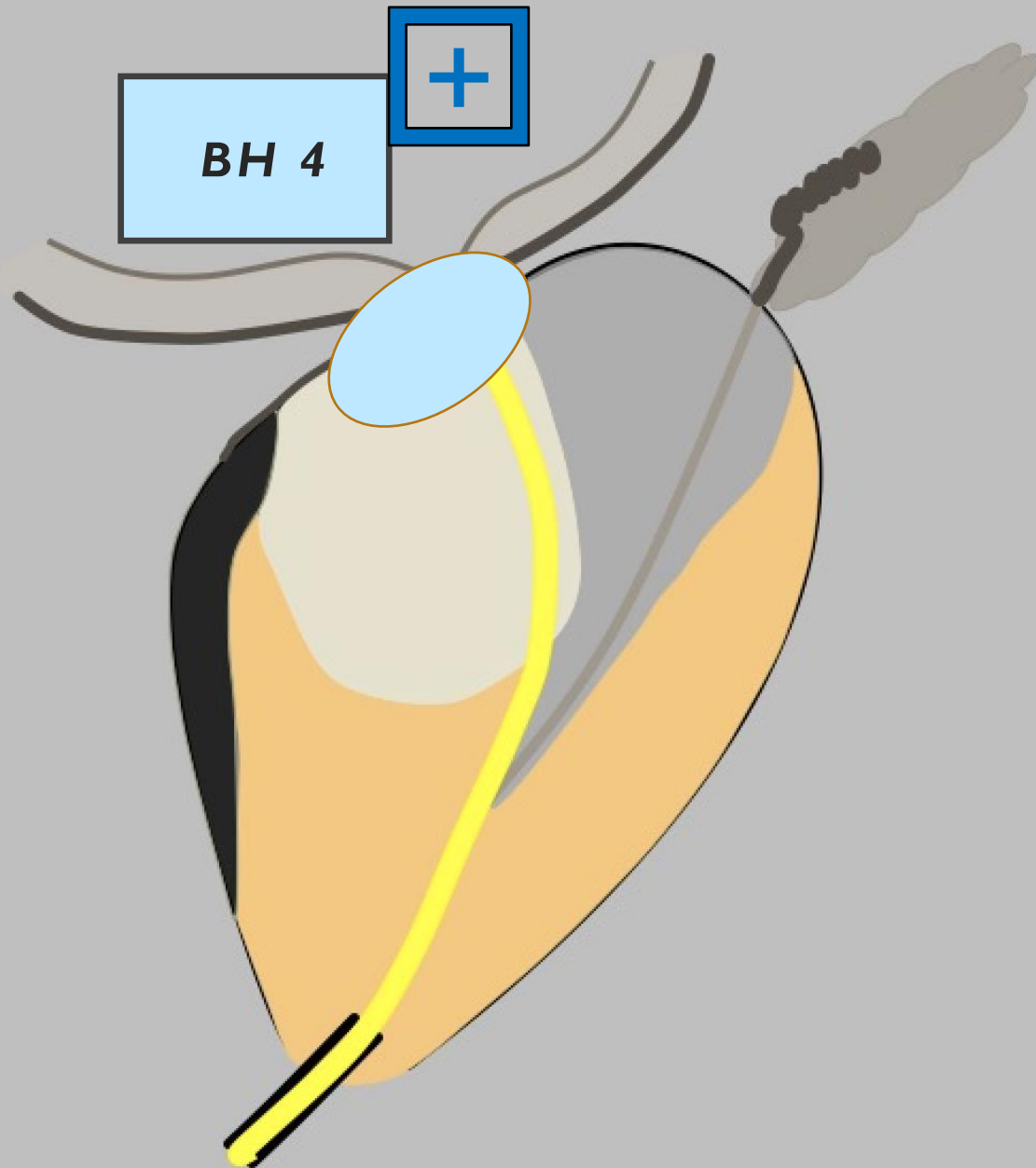


Tumören når upp i blåshalsen, men utan att säkert växa över. Bibehållen signal i blåshalsväggen på sagittal bild (svarta pilar).

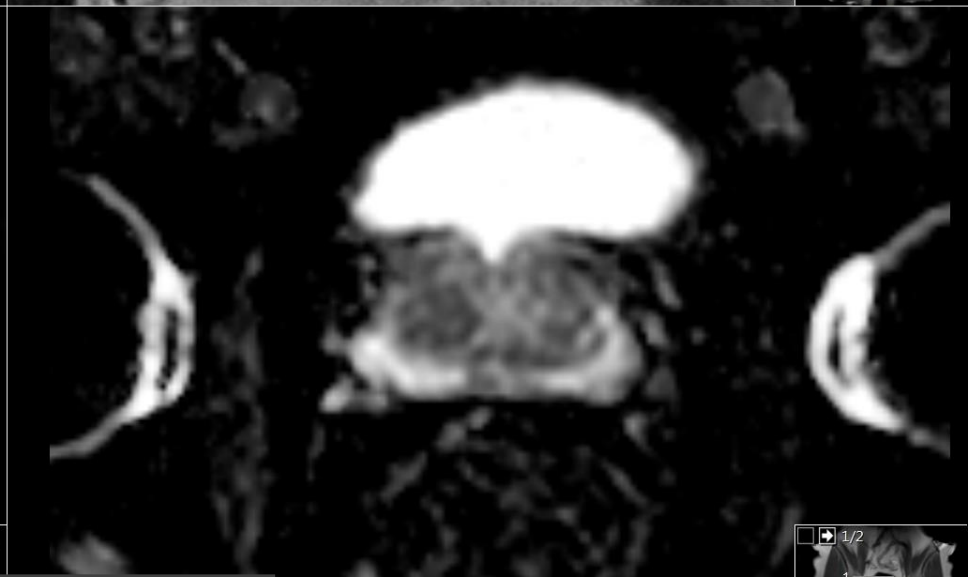
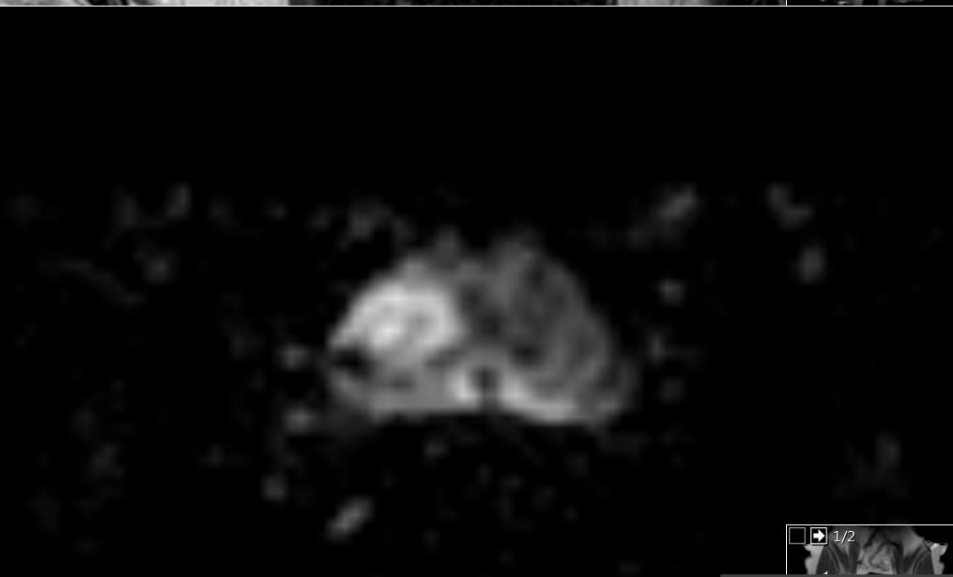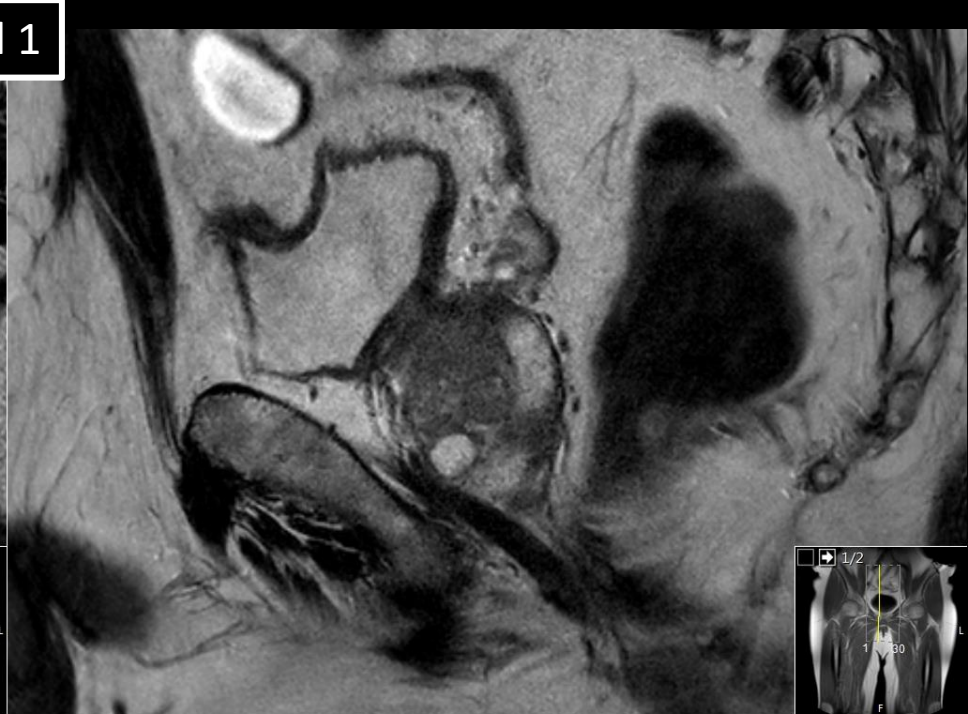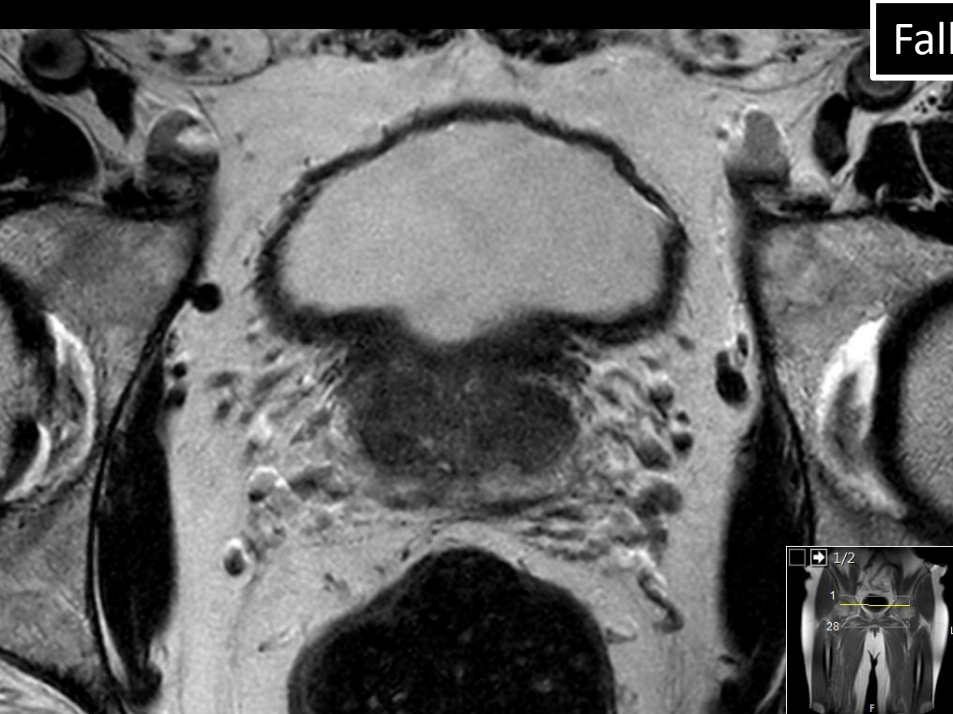


BLÅSHALS 3

BLÅSHALS (BH)



Fall 1



BLÅSHALS 4

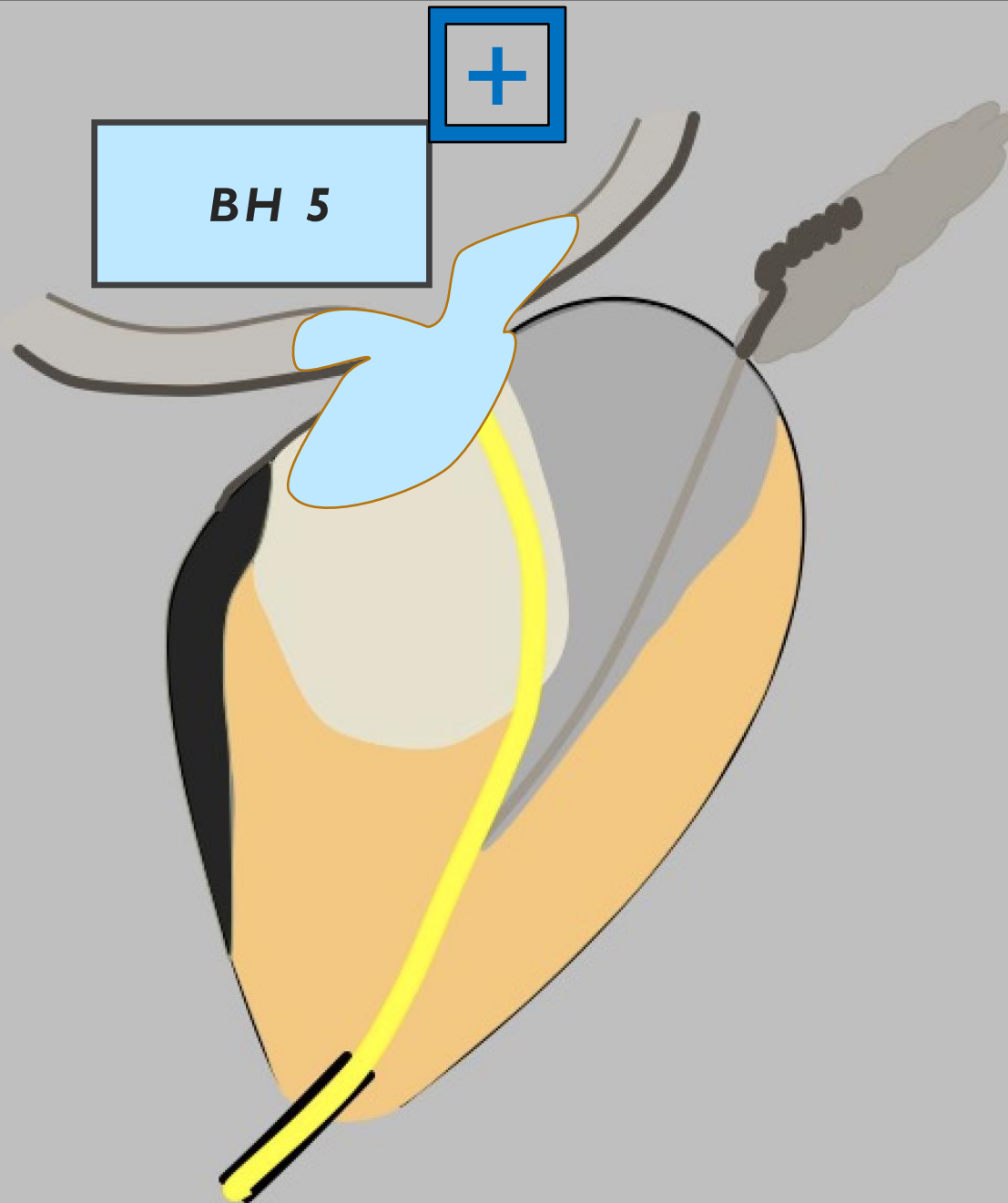
Fall 1

Tumörsignal i blåshalsväggen

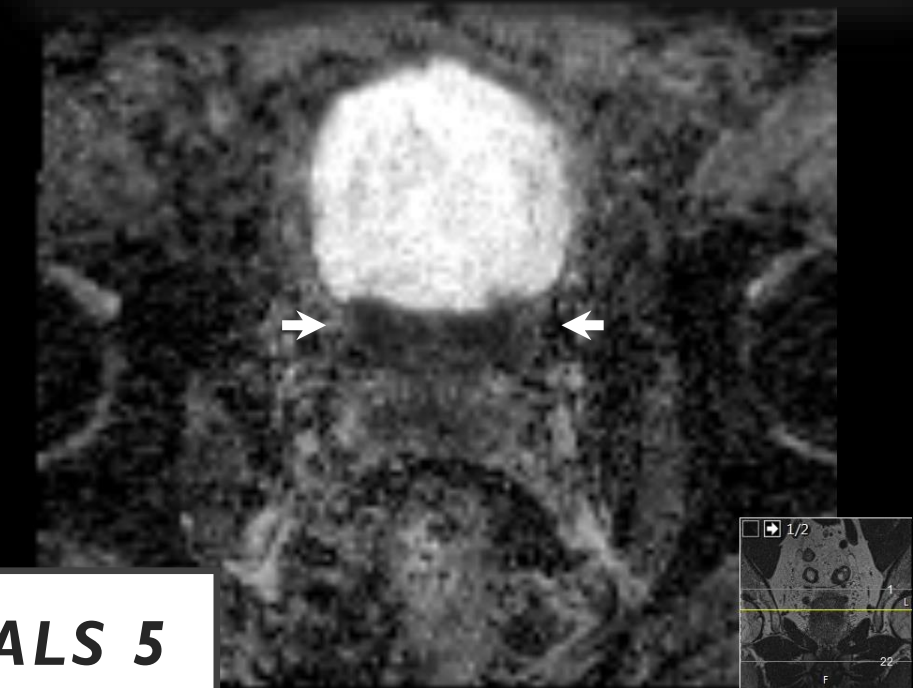
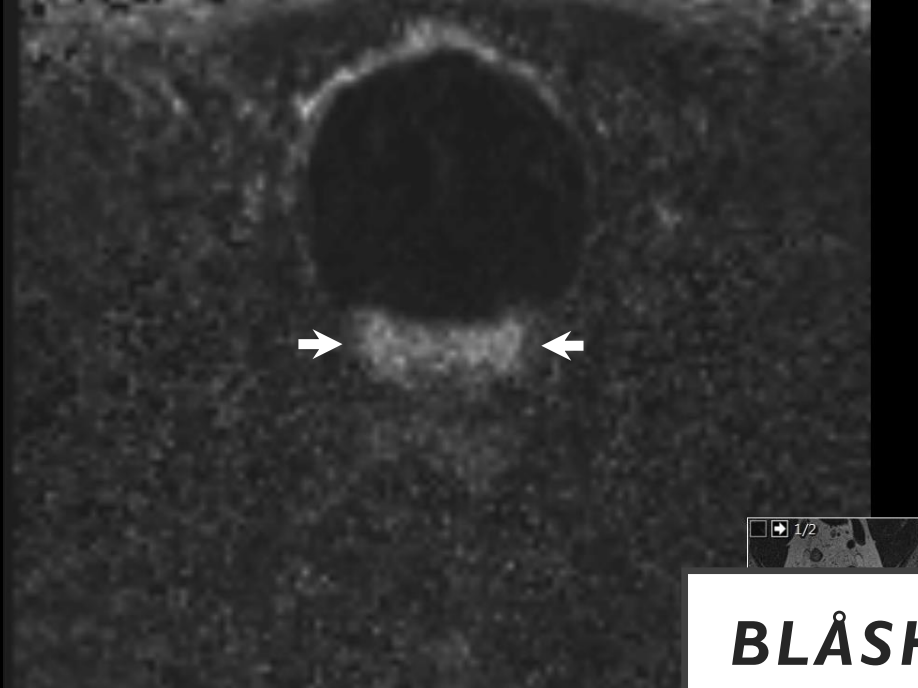
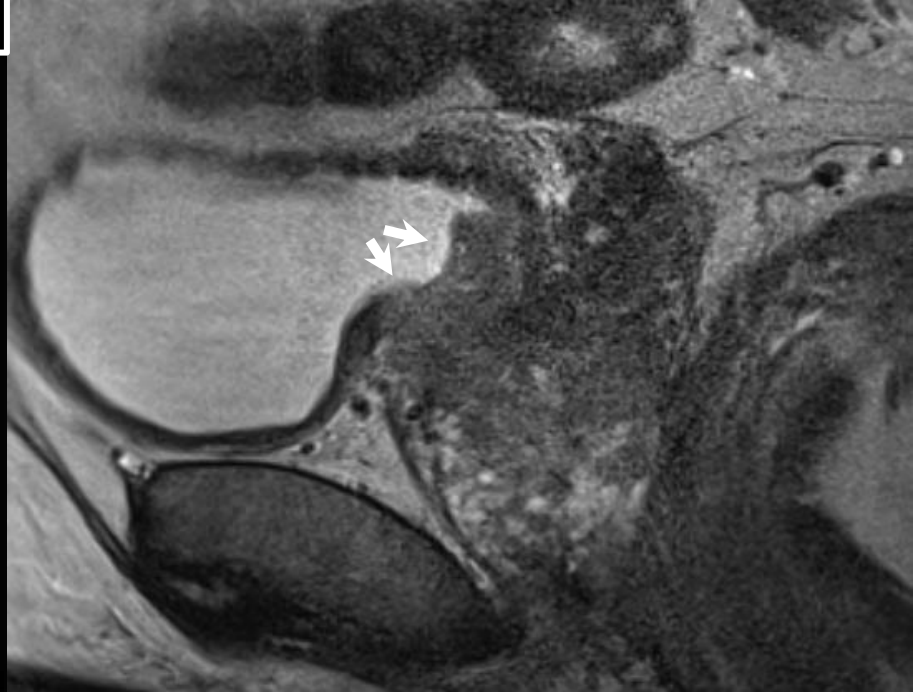
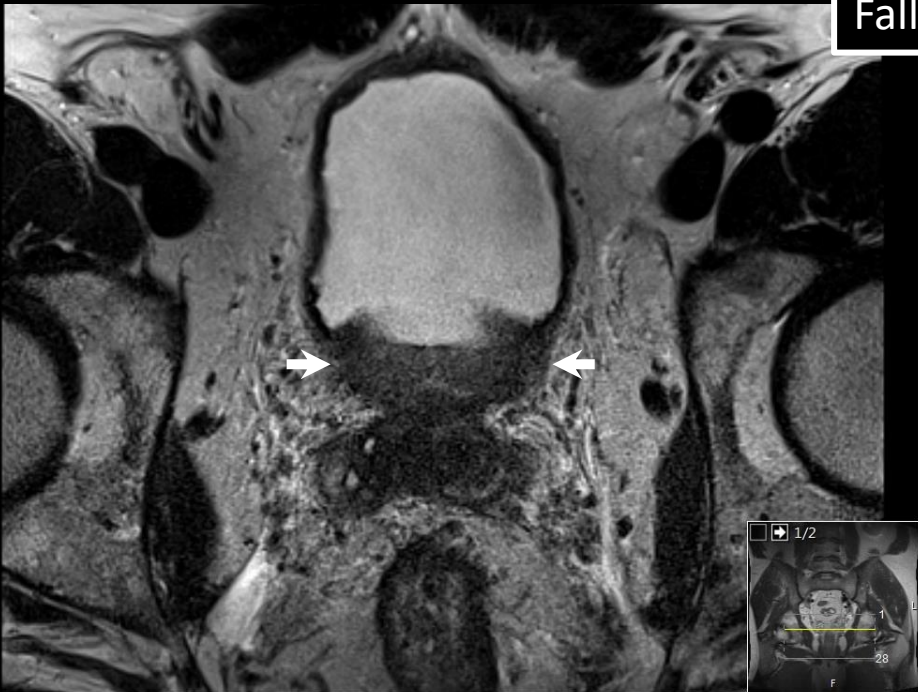

BLÅSHALS 4

BLÅSHALS (BH)

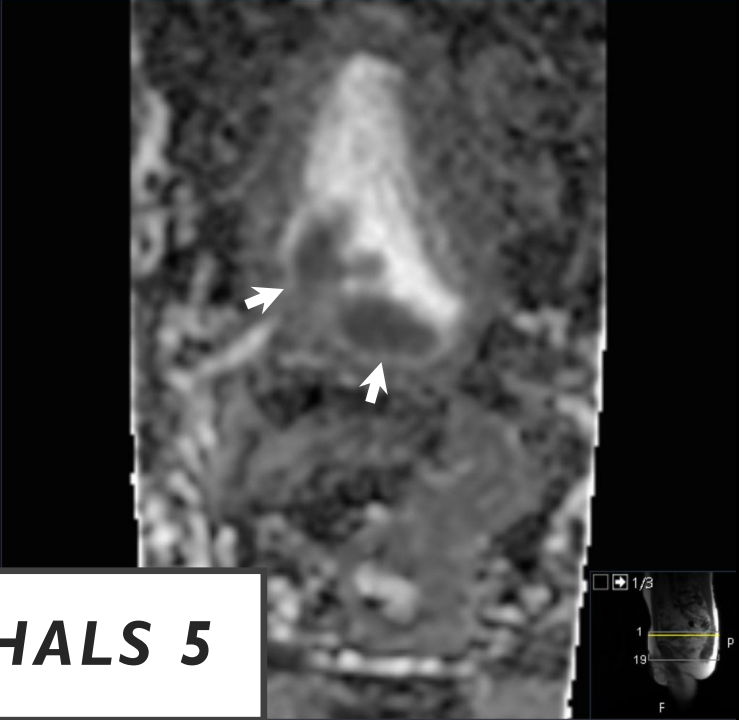
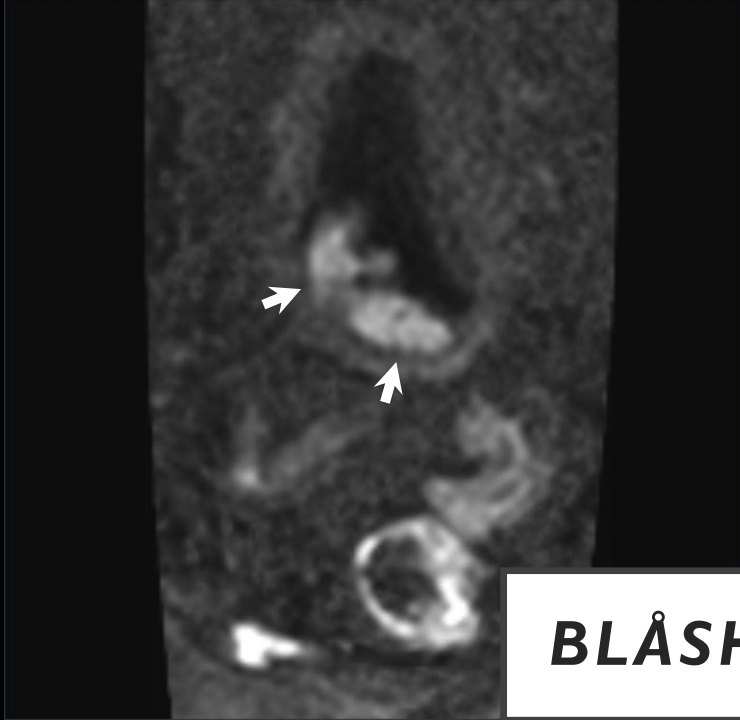
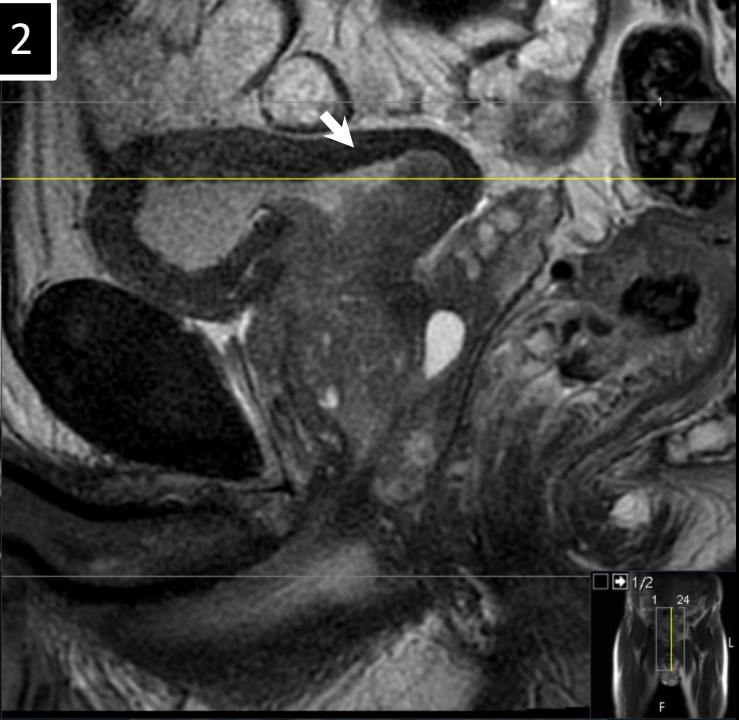
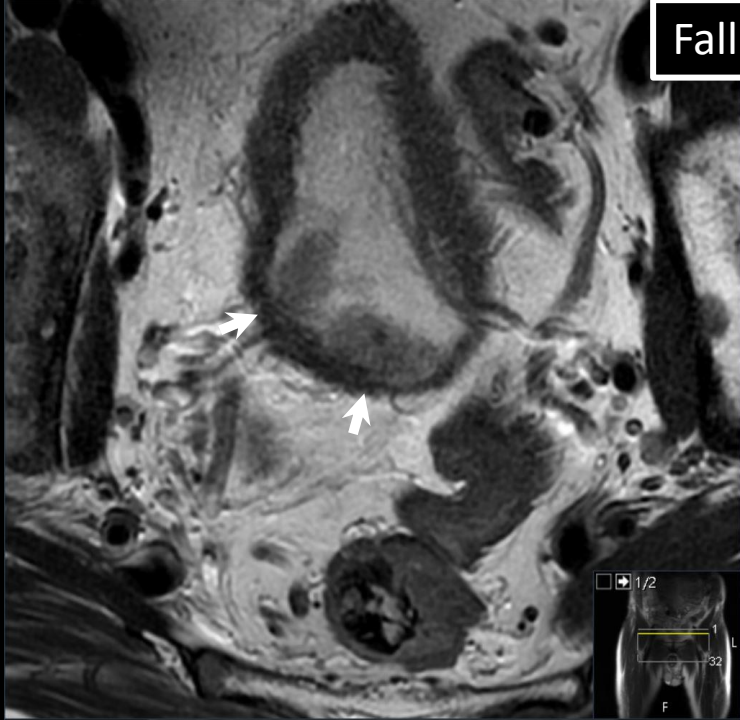


Fall 1



BLÅSHALS 5

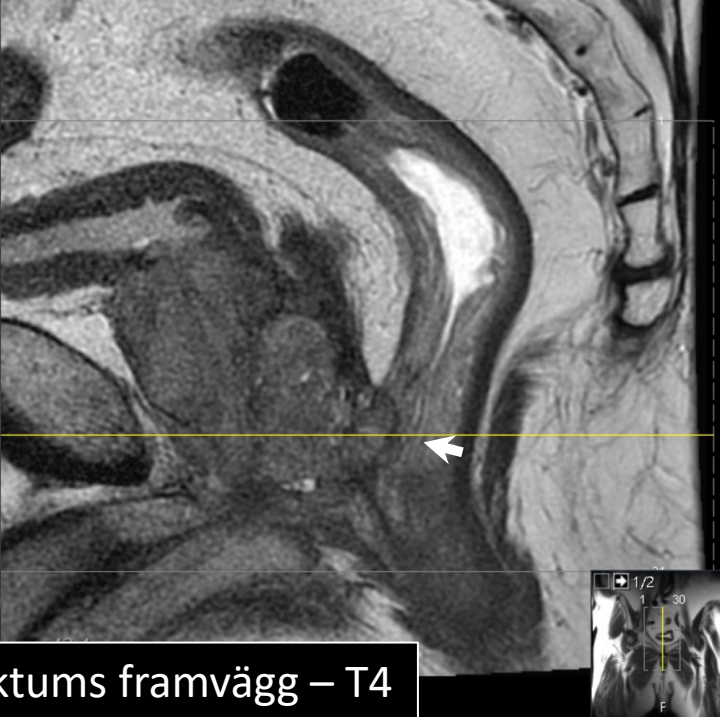
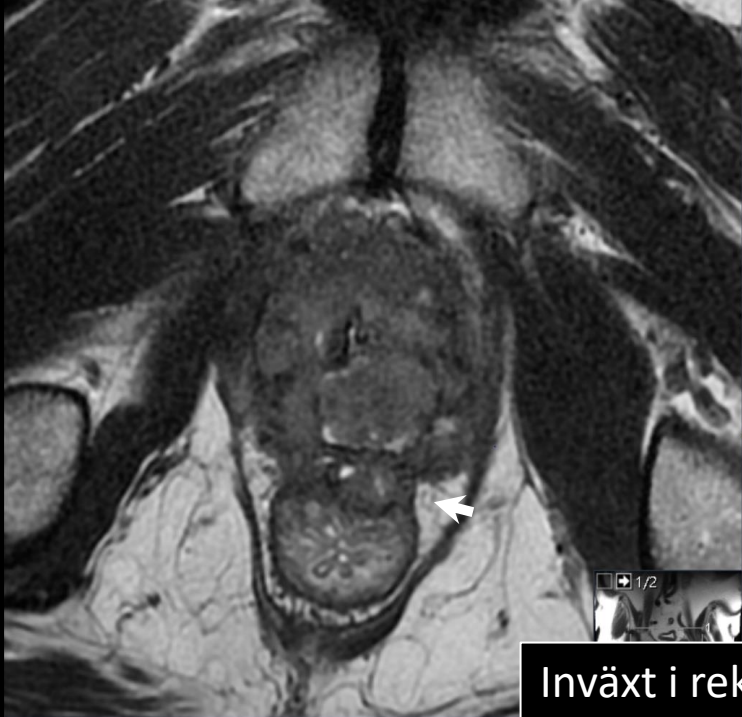Fall 2



BLÅSHALS 5

STADIEINDELNING

- LOKALT AVANCERAD TUMÖR T4



Inväxt i rektums framvägg – T4

